

# A Case of Papillomatous Digital Dermatitis in Feedyard Cattle

Brian V. Lubbers, DVM; Michael Apley, DVM, PhD, DACVCP

Department of Clinical Sciences, College of Veterinary Medicine, Kansas State University, Manhattan, KS 66506

## Abstract

Papillomatous digital dermatitis may be an emerging disease within the feeder cattle industry. This case report will review the presentation, diagnostic plan and some of the available treatment options as well as describe an atypical presentation of this disease.

## Résumé

La dermatite digitée papillomateuse peut être une maladie émergente dans l'industrie des bovins en engraissement. Ce rapport de cas fait le point sur l'apparence normale et parfois inhabituelle de cette maladie, le plan diagnostique et quelques uns des traitements disponibles.

## Introduction

Papillomatous digital dermatitis or PDD is a common cause of lameness in dairy cattle around the world.<sup>1,3,5,8</sup> Also known as hairy heel warts, strawberry footrot, or Mortellaro's disease, PDD was first reported as a contagious disease in the United States in 1980 after an outbreak in two New York dairies.<sup>7</sup> This disease had become so widespread within the dairy industry by 1996 that the USDA included PDD in that year's NAHMS dairy survey. In that survey, 47% of participants reported having at least one case of PDD in cows or bred heifers within the previous 12 months.<sup>4</sup> A prevalence study by Brown, Kilgo and Jacobsen found PDD lesions in 4% of culled adult beef cattle in the southeastern United States.<sup>2</sup> Although the etiology has not been definitely proven, the current focus is on spirochetes of the genus *Treponema*. Despite the extensive amount of research devoted to the treatment and control of this disease in the dairy industry, little information is available concerning PDD in feedyard cattle.

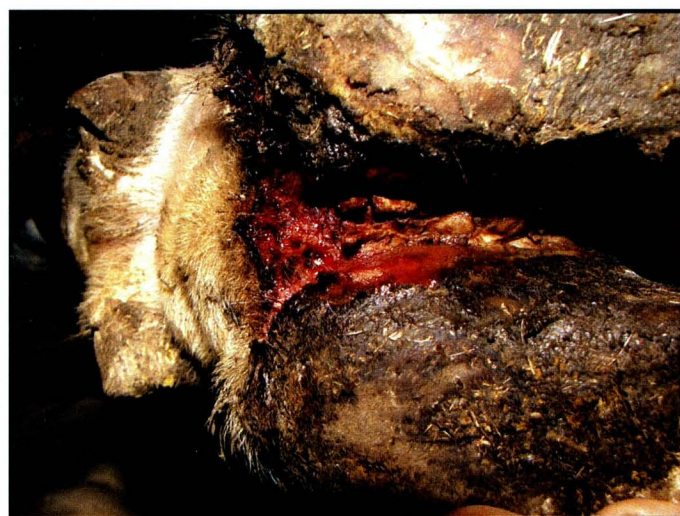## History

In September 2005 a Kansas feedyard reported an outbreak of footrot that was non-responsive to treatment with parenteral oxytetracycline. Approximately 15 pens of cattle were affected, with the total number of cases

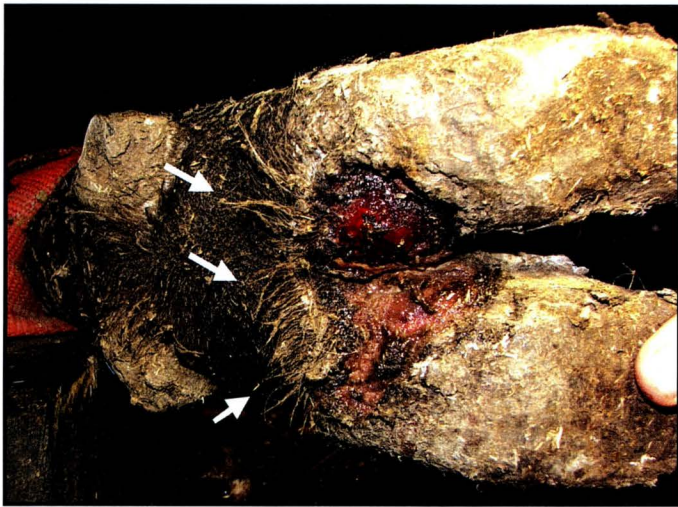
estimated at 300 out of an at-risk population of approximately 25,000. Five affected heifers were presented to the Kansas State University Veterinary Medical Teaching Hospital on September 12, 2005 for further diagnostics. All five animals were severely lame upon presentation. Four heifers had erosive lesions of the digital skin in either the interdigital space or at the palmar/plantar aspect of the coronary band (Image 1). Forelimbs and hindlimbs were affected, with some animals having multiple limbs affected. One heifer presented with a proliferative lesion suggestive of papillomatous digital dermatitis (Image 2). Biopsies of the lesions were taken and submitted for routine histopathology and silver staining to identify *Treponema* sp.

## Laboratory Data from Initial Examination

Routine histopathology of biopsies showed a hyperplastic epidermis with neutrophilic inflammation of the superficial epidermis and underlying dermis. On silver stain large numbers of filamentous bacteria and spirochetes were seen infiltrating the epidermis. Aerobic cultures yielded growth of non-hemolytic *E. coli*, alpha hemolytic *Streptococcus* sp., *Bacillus* sp. and *Staphylococcus* sp. These results were consistent with a diagnosis of papillomatous digital dermatitis.



**Image 1.** Erosive lesion involving interdigital space and palmar aspect of right forelimb.



**Image 2.** Classic Papillomatous Digital Dermatitis lesion – Note the erect elongated hairs associated with the lesion (arrows).



**Image 3.** Typical stance of cattle affected with papillomatous digital dermatitis.

### Field Investigation

Following the initial examination of animals at Kansas State University, a visit was made to the feedyard on September 28, 2005 to examine affected animals, collect soil samples, and provide recommendations to feedyard management. Tulathromycin<sup>b</sup>, ceftiofur HCL<sup>c</sup>, ceftiofur crystalline free acid<sup>d</sup> and procaine penicillin G (various generic products) were discussed as potential therapeutics based on characteristics of *Treponema* and spectrum of activity for these antimicrobials.

A second visit was made to the feedyard on October 24, 2005 to collect additional biopsies and to evaluate response to previously initiated treatment measures. Animals examined were of similar clinical presentation to animals examined at the Kansas State University Veterinary Teaching Hospital (Image 3). An Excenel<sup>TM</sup> regimen (1.1 mg/lb; 2.2 mg/kg subcutaneously (SC), twice, 48 hours apart) proved to be effective at resolving clinical lameness. This regimen was tested on 10 animals in conjunction with a positive control of 10 affected animals treated with 200 mg/ml long-acting oxytetracycline.<sup>a</sup> While not a completely randomized trial, the animals receiving the ceftiofur HCL displayed resolution of lameness by 10-14 days while the oxytetracycline treated cattle showed no improvement in lameness. The experience at this feedyard was that untreated cattle did not spontaneously resolve.

The use of single injections of tulathromycin at 1.14 mg/lb (2.5 mg/kg) SC and ceftiofur crystalline free acid at 3.0 mg/lb (6.6 mg CE/kg) SC in the ear also resulted in clinical resolution of lameness, usually within 10-14 days. Treatments were assigned to cattle on an every-

other-head basis through the treatment chute. Observations were not masked, as treated cattle were identified by colored eartags. However, these experiences do suggest that randomized, masked, prospective clinical trials are appropriate to evaluate the use of tulathromycin and ceftiofur for treatment of PDD in feedlot cattle. A single intramuscular injection of procaine penicillin G (15,000 IU/lb; 33,000 IU/kg) was not successful at resolving lameness caused by PDD.

Biopsies were sent to the National Animal Disease Center in Ames, IA, for *Treponema* identification and culture. Three of nine environmental samples and all six digital skin biopsies were positive for *Treponema* through either dark field microscopy or culture. The significance of the treponemes in PDD is still under scientific investigation. The organisms are consistently isolated from lesions, but the pathogenesis remains unclear.<sup>6</sup> Genetic sequencing is currently being used to identify the relationship between environmentally-isolated and tissue-isolated treponemes.

### Management

The heifers seen at the Kansas State University Veterinary Medical Teaching Hospital were treated with topical oxytetracycline powder under a bandage and responded favorably. However, topical application of antibiotics was not practical in the feedyard due to the number of animals affected. Feedyard management chose not to use footbaths as a treatment option due to the excessive handling required and concerns with compounds to be used. Reasonable clinical responses had been achieved through parenteral administration of antibiotics. Due to the total treatment cost and stage of the feeding period for affected animals, the ceftiofur HCL

regimen described above was selected for use in future cases. As of the writing of this proceedings article, this feedyard had experienced another smaller outbreak of papillomatous digital dermatitis, but early recognition and aggressive treatment had minimized the number of cattle affected. The latest outbreak occurred primarily in pens unaffected in the previous outbreak.

### Prevalence in Feedyards

The lack of information on this specific presentation of PDD prompted concerns about prevalence of this disease in feedyard cattle. To begin to determine prevalence in feedyards, a brief survey has been completed by 23 feedyard consulting veterinarians to date. Respondents reported that their clients fed approximately five million cattle in 2005 and conservatively estimated seeing 935 cases of PDD in the last two years. Four veterinarians reported seeing the disease but failed to estimate number of cases seen.

### Discussion

Papillomatous digital dermatitis presents a unique problem in feeder cattle. In the case reported here, the majority of lesions seen were not typical of PDD in gross appearance. Past research in dairy cattle can be applied to a limited extent but due to potential problems with disease recognition, treatment and management in the feedyard, future outbreaks must be addressed with feedyard-specific solutions. Clinical trials are necessary to determine the performance cost of this disease and to demonstrate the most effective treatment and control strategies.

### Endnotes

- <sup>a</sup>Liquamycin® LA-200, Pfizer Animal Health, New York, NY
- <sup>b</sup>Draxxin™, Pfizer Animal Health, New York, NY
- <sup>c</sup>Excenel™, Pfizer Animal Health, New York, NY
- <sup>d</sup>Excede™, Pfizer Animal Health, New York, NY

### Acknowledgements

The authors would like to thank Dr. Margaret Elliott and Mr. Richard Hornsby at the NADC, Ames, IA, for their cooperative efforts during this investigation.

### References

1. Blowey RW, Done SH, Cooley W: Observations on the pathogenesis of digital dermatitis in cattle. *Vet Rec* 135(5):115-117,1994.
2. Brown CC, Kilgo PD, Jacobsen KL: Prevalence of papillomatous digital dermatitis among culled adult cattle in the southeastern United States. *Am J Vet Res* 61(8): 928-930, 2000.
3. Cruz C, Driemeier D, Cerva C, Corbellini L: Bovine digital dermatitis in southern Brazil. *Vet Rec* 148(18): 576-577, 2001.
4. <http://www.aphis.usda.gov/vs/ceah/ncahs/nahms/dairy/dairy96/DR96digderm.pdf> Accessed: March 14, 2006
5. Kimura Y, Mashiro T, Matsumoto N, et al: Verrucose dermatitis and digital papillomatosis in dairy cows. *J Vet Med Japan* 46:899-906, 1993.
6. Personal communication. Deryck Read. January 11, 2006.
7. Rebhun, WC, Payne RM, King JM, et al: Interdigital papillomatosis in dairy cattle. *J Am Vet Med Assoc* 177:437-440, 1980.
8. Rodriguez-Lainz A, Hird DW, Walker RL, Read DH: Papillomatous digital dermatitis in 458 dairies. *J Am Vet Med Assoc* 209:1464-1467, 1996.