

A chance to cut is a chance to cure: Practical tips for performing a rumenostomy

Elizabeth R. Homerosky, DVM, MSc, DABVP (Beef Cattle Practice)

Veterinary Agri-Health Services Ltd., 201-151 East Lake Blvd. NE, Airdrie, Alberta, T4A 2G1, Tel: +1 403 948 2253, Email: elizabethh@vahs.net (Dr. Elizabeth R. Homerosky)

Abstract

A rumenostomy is a quick and easy surgery that can help remedy recurrent bloat refractory to medical therapy. This clean-contaminated surgery is particularly useful among cattle experiencing chronic vagal indigestion, and is a common surgery performed in feedlot cattle. Preoperative analgesia should be provided; however, choice of antibiotic therapy is generally left to the discretion of the surgeon. Following local anesthesia and surgical prep of the left paralumbar fossa, a circular incision is made through the skin. Muscle layers are removed or bluntly dissected and the peritoneum is incised to visualize the rumen. The rumen wall is exteriorized and stay sutures are applied to reduce the risk of rumen contents contaminating the abdomen. A stoma into the rumen is created and a tight seal between the rumen wall and skin is achieved via several different suture pattern options. Patient prognosis is generally good regardless of surgical technique, pending no severe underlying medical conditions are present.

Key words: rumen fistula, bloat, vagal indigestion, feedlot cattle

Résumé

La ruménostomie est une chirurgie rapide et facile qui peut aider à remédier le ballonnement récurrent réfractaire au traitement médical. Cette chirurgie propre-contaminée est particulièrement utile chez les bovins qui souffrent d'indigestion vagale chronique et est souvent utilisée chez les bovins dans les parcs d'engraissement. L'analgésie préopératoire est requise mais le choix de la thérapie antibiotique est généralement laissé à la discrétion du chirurgien. Après l'anesthésie locale et la préparation à la chirurgie de la fosse paralombaire gauche, une incision circulaire est faite à travers la peau. Les couches musculaires sont enlevées ou disséquées grossièrement et le péritoine est incisé pour exposer le rumen. La paroi du rumen est extériorisée et des sutures de fixation sont appliquées pour réduire le risque que le contenu du rumen contamine l'abdomen. Une stomie dans le rumen est créée et un joint étanche entre la paroi du rumen et la peau est établi en utilisant diverses options de type de sutures. Le pronostic pour le patient est généralement bon peu importe la technique chirurgicale sauf s'il existe d'autres conditions médicales sous-jacentes sévères.

Introduction

A rumenostomy is a clean-contaminated standing surgical procedure commonly performed in a feedlot setting. It is considered adjunct therapy for the treatment of recurrent free gas bloat.³ Surgery is warranted when orogastric intubation is unsuccessful or daily intubations are required. The author recommends performing a rumenostomy in cases refractory to medical therapy, where intubation is required for more than 3 consecutive days. Trocarization is strongly discouraged due to likelihood of peritonitis, but is occasionally performed in emergency situations, such as respiratory distress.³ In these cases, it is recommended that a rumenostomy encompassing the trocarized location be performed as soon as possible. A rumenostomy may provide short to long-term relief of rumen tympany while underlying predisposing diseases or conditions are given time to resolve.¹

Preoperative Considerations and Ancillary Therapy

A thorough clinical examination should be performed before electing to perform a rumenostomy.

Performing orogastric intubation is recommended to rule out the possibility of frothy bloat. Cattle experiencing frothy bloat are predisposed to severe complications such as peritonitis and should not be considered surgical candidates. Collecting an adequate history is also of upmost importance. If there is no history of treatment for bovine respiratory disease (BRD), but pneumonia is diagnosed upon clinical examination, the author will often recommend antibiotic treatment for first pull BRD per protocol. If the history reveals treatment for BRD, then that should also be taken into consideration as the free-gas bloat is likely a sequela to vagal indigestion. Though not fully described, damage to the vagus nerve or enlarged mediastinal lymph nodes resulting from pneumonia, fibrinous pleuritis, or other intrathoracic inflammation are believed to inhibit normal rumenations and eructation.¹ Cases diagnosed with chronic pneumonia and in poor body condition should not be considered surgical candidates, as a rumenostomy will not remedy the underlying issue.

Cases of recurrent free gas bloat with no history or evidence of disease are likely to result from dietary causes. The risk of surgical complications increases among cattle over 1000 lb (454 kg) and it is recommended these cattle be marketed to the packer as soon as possible. Although

increasing roughage in the diet is ideal, this may not be practical for lighter cattle and performing a rumenostomy is often the most economical solution. The author does not routinely administer antibiotics in these types of cases. However, if surgical complications occur and peritonitis is of concern, broad-spectrum antibiotics such as ampicillin or oxytetracycline are prescribed, depending on animal weight and reasonable allotted time for meat withdrawal.

Analgesia and local anesthesia should be administered preoperatively. Meloxicam is highly recommended for long-term analgesia. The most common form of local anesthesia is subcutaneous and intramuscular lidocaine administered in an inverted-L pattern in the left paralumbar fossa following clipping and the first surgical scrub. The use of drapes is inconsistent among feedlot practitioners and commonly left to the discretion of the surgeon.¹ Good restraint throughout the procedure is critical, and in some cases it may be advantageous to restrain the left hind limb.

Surgical Technique

A number of surgical techniques including various sized circular, elliptical, and linear incisions have been observed and are noted to result in similar outcomes.¹ Following full surgical site preparation, the author makes a silver dollar-sized circular incision 2 to 3 fingers caudal to the last ribs and 2 to 3 fingers ventral to the transverse processes using a #22 scalpel blade. Subcutaneous tissues and the external oblique muscle layer are excised. The internal oblique and transversus abdominis muscles should not be surgically excised unless the surgeon exemplifies notable experience and skill. Rather, blunt dissection to the level of the peritoneum is preferred.

Before entering the abdomen, the peritoneum should be retracted using hemostats to ensure the rumen is not prematurely incised. Severe rumen distension will complicate this step, however, alleviation of gas should have been achieved by passing an orogastric tube during the preoperative examination. Scissors should be used to extend the incision through the peritoneum. It is common for the animal to react as the peritoneum will not be anesthetized. One or 2 digits should be used to palpate the medial side of the peritoneum to ensure no adhesions are present. A pair of towel clamps are then used to retract and exteriorize the rumen.

Pending no adhesions or other complications, 4 stay sutures are placed to secure the rumen wall in place. The author prefers to place 2 cm horizontal mattress sutures in the 1:30, 4:30, 7:30, and 10:30 positions so that the hanging towel clamp placed on the rumen does not interfere with stay suture placement (Figure 1). The rumen serosa should be tightly apposed to hypodermis. Next, a quarter-sized circular incision is made into the rumen causing the freshly cut edges to evert.

A variety of suture materials and patterns can be utilized to create a tight seal between the rumen wall and

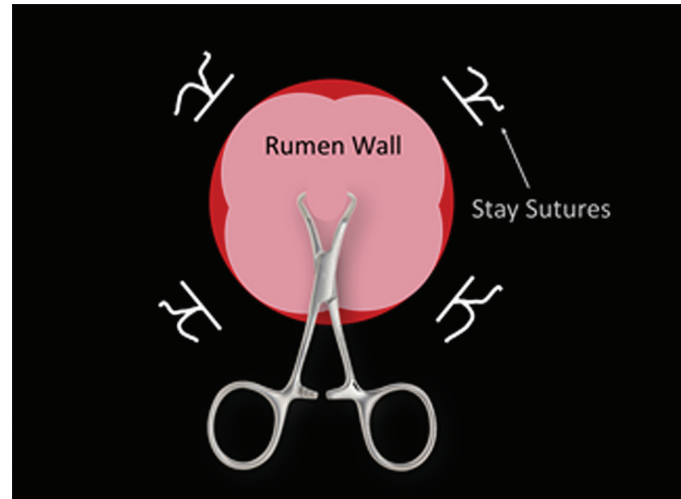


Figure 1. Depiction of stay sutures used to appose rumen wall to skin before incising the rumen.

skin. The author prefers 3 catgut chrom in a simple continuous pattern using an S-curve needle due to ease and speed; however, supramid in a simple interrupted pattern provides enhanced security. The suture is started in the 12:00 position and continues from skin to rumen (right to left) in a clockwise fashion. Sutures should be placed no more than 1 cm apart approximately 1 cm from the freshly incised skin in order to create a tight seal. The author ties off the suture at the 6:00 position. This achieves 3 things: 1) provides enhanced security in the event that the suture line breaks, 2) prevents the creation of a purse-string effect, thereby maintaining the original size of stoma, and 3) allows the surgeon to change the direction of the suture if so desired. Restarting the simple continuous suture pattern at the 6:00 position allows the surgeon to continue suturing from right to left by going from rumen to skin. The suture line is completed in the 12:00 position and the site is cleaned and checked for a tight seal (Figure 2). Simple interrupted sutures should be placed in any locations where rumen wall and skin are not tightly apposed to prevent contamination of the abdominal wall or abdomen. The stay sutures are often left in place.

Granulation tissue should create a tight seal by 2 weeks following surgery and sutures may be removed. In some cases, the stoma may prematurely close by second intention. However, a cannula or syringe casing may be placed to ensure the rumenostomy remains patent.¹

Prognosis and Follow-up Therapy

Prognosis following a rumenostomy is generally regarded as good. It is estimated only 13% of surgical candidates experience short-term complications such as incisional infection, peritonitis, or death.² In many cases, death is attributed to the underlying disease causing recurrent free gas bloat, such as BRD, and is not directly related to the surgery itself.

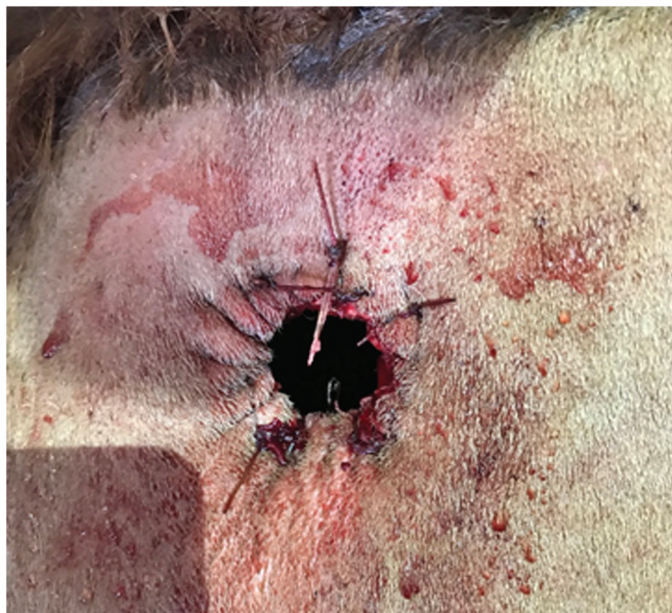

Figure 2. Completed rumenostomy site with adequately apposed rumen wall and skin using a simple continuous suture pattern.

On rare occasions the author has witnessed hysteria among animals immediately following surgery. It is hypothesized that fluid sounds and expelled steam arising from the surgical site frighten the animal. In a failed attempt to escape the unfamiliarity, panicking cattle occasionally run directly into fences or gates, sustaining severe life-threatening injuries to the cranium or spinal column.

The most common long-term complication is premature closure of the stoma. A second rumenostomy is not warranted, as the rumen should be tightly adhered to the interior abdominal wall. Rather, it is recommended that a stainless steel trocar be inserted through the center of the fibrotic tissue and secured in place using supramid suture.

Conclusion

A rumenostomy is a quick and easy surgery that can help remedy recurrent bloat refractory to medical therapy. This clean-contaminated surgery is particularly useful among cattle experiencing vagal indigestion as a sequela to pneumonia or fibrinous pleuritis and is a common surgery performed in feedlot cattle. Preoperative analgesia should be provided; however, choice of antibiotic therapy is generally left to the discretion of the surgeon. Numerous surgical techniques have been observed and typically yield similar results as long as a tight seal between the rumen wall and skin is achieved. Patient prognosis is generally good, pending no severe underlying medical conditions are present.

Conflicts of Interest

The author declares no conflicts of interest.

References

1. Callan RJ, Applegate TJ. Temporary rumenostomy for the treatment of forestomach diseases and enteral nutrition. *Vet Clin North Am Food Anim Pract* 2017;33: 525–537.
2. Hartnack AK, Niehaus AJ, Rousseau M, et al. Indications for and factors relating to outcome after rumenotomy or rumenostomy in cattle: 95 cases (1999-2011). *J Am Vet Med Assoc* 2015;247:659–664.
3. Lozier JW, Niehaus AJ. Surgery of the forestomach. *Vet Clin North Am Food Anim Pract* 2016;32:617–628.