

Cattle prolapse management

Corale M. Dorn, DVM
Dells Veterinary Services, PC
Dell Rapids, SD 57022

Abstract

There are already numerous journal articles and sections in books that describe the various forms of prolapses in cattle and the underlying causes and methods of correction. This article starts with essential techniques no matter what type of prolapse is present. This article includes proper epidural placement, pain management, topical therapies, suture selection, the timing of correction, and most importantly, the client conversations that should happen while managing prolapses. After that review, there will be a section for each of the most common types of bovine prolapses that will include the risk factors to look for during the initial exam, the technique for correction, additional medications warranted, and the proper follow-up care and client communication.

Key words: prolapse, rectal, vaginal, uterine, client education

Introduction

In an age where classic veterinary services can be undervalued (e.g., performed by a layperson, replaced by a commercial lab test or altogether skipped), there is less debate regarding prolapses. A piece of flesh outside the bovine creates an undeniable need for intervention by a practitioner, if for no other reason than the legal requirements outlined in the USDA antemortem inspection. While not glorious work, prolapse management is yet another area for new graduates to tackle a difficult job to gain a producer's trust and lobby for additional services they could provide.

This paper will guide the new veterinarian and serve as a general review of referenced literature concerning how to deal with prolapses in cattle while maintaining a healthy focus on serving the client. This paper will individually discuss each of the 3 prolapses while covering the risk factors for developing this prolapse, the technique to correct the prolapse, and the client discussions that should be involved.

Timing and scheduling

Prevention is always ideal with prolapses, and the veterinarian should perform a physical exam to identify underlying risks that could cause other cattle on the premise to prolapse. However, correcting the prolapse as soon as possible can improve the prognosis if a prolapse has already occurred.¹ Veterinarians can work with their clinic staff that takes incoming calls so they can correctly identify the prolapse and the urgency. Phrases like "top hole" along with the gender and age of the animal help prepare the veterinary team for the rectal prolapse and underlying problem that should be repaired before the rectal mucosa freezes or is damaged. However, it can wait for 2-3 hours until later in the appointment block that same day. Cattle with a "bottom hole" prolapse in a female bovine that could vary from "size of a softball" to "a beach ball" should be asked further questions, including "has she calved yet?" These vaginal prolapses should still be repaired the same day to preserve mucosal integrity but can wait 2-3 hours. Cows with a "bottom hole" prolapse "the size of a feed sack with purple buttons" and

a calf lying behind her are an emergency. The staff should route the veterinarian to repair that uterine prolapse as soon as possible. Staff at veterinary hospitals appreciate a review of these conditions before calving season each year, along with a review of hospital policy about getting them on the schedule.

Pain management

All written articles on prolapse management start with caudal low-dose epidural analgesia as a standard of medicine. The caudal low-dose epidural analgesia location is either the sacrococcygeal intervertebral space (S5-Co1) or the first coccygeal intervertebral space (Co1-Co2). The injection site for the epidural should be confirmed by moving the tail up and down and identifying the first joint space caudal to the sacrum that moves while the tail is pumped.² Advance an 18 G x 1 1/2" needle slightly cranially into the epidural space until you hear a pop. Well-written papers describe placing a drop of lidocaine into the hub of a needle at the sacrococcygeal site and watching to ensure that the lidocaine was drawn into the epidural space.³ In practice in the windy field, it is reasonable to determine that placement is correct if the lidocaine can be injected with no resistance or blood in the hub. There are techniques described that utilize lidocaine alone (0.22 mg/kg) or a combination of 2% lidocaine (0.22 mg/kg) and xylazine (0.05 mg/kg). This combination allows for prolonged anesthesia but may result in ataxia.² Some practitioners prefer using 2% lidocaine with epinephrine (lidocaine HCl 2% with epinephrine; Bimeda Mtc, Cambridge, Ontario), 0.6 mg/kg BW for more prolonged analgesia without the ataxia of xylazine.³ There are descriptions in the literature of using ethyl alcohol for epidurals; they should be used with extreme caution, if at all.⁴ While they can be an economical alternative, they may result in long-term complications ranging from fecal contamination of the perineum, tail paralysis, urine retention and ataxia up to the animal's death. Another complication can be a client that retains the cull animal because she no longer strains.

Additional medication

Beyond the caudal epidural analgesia, anti-inflammatory medication should be considered if there is severe local tissue swelling after the prolapse is replaced. Veterinarians report using flunixin either as flunixin meglumine 50 mg/ml at a dose of 1.1 - 2.2 mg/kg IV in beef and dairy⁵ OR flunixin in an approved transdermal solution (Banamine Transdermal®) at a dose of 3.3 mg/kg transdermally for beef females and dairy females < 20 months of age.⁵ However, flunixin for inflammation is an extra label in both of these formulations. Furthermore, flunixin meglumine inhibits the production of prostaglandins and prolongs impending labor for up to 48 hours. If the veterinarian wants to use this drug for pain and inflammation, a clear veterinary client-patient relationship should exist along with appropriate identification, records and withdrawals. Antibiotics may be warranted depending on the degree of tissue damage and necrosis in the prolapse along with the production setting. Any medication given should be at the discretion of a veterinarian

in a client-patient relationship setting. Antibiotics are almost always needed if a cow is nursing a live calf or milking in the herd and a suture is placed.

Suture selection

The ability of the cattle's tissue to hold the prolapse inside is directly correlated to the amount of surface area included in the repair. Wide suture material (such as 3/8" umbilical tape) should be applied across a thick tissue bite to maximize the surface area and ensure the best outcomes. Using standard bovine surgical suture material, absorbable or non-absorbable, does not work well for the retention of prolapses because the thin diameter of the suture will cause the accumulating pressure to slice through the tissue that the suture is meant to hold. While umbilical tape has an advantage over traditional sutures, it does have two distinct drawbacks. The first is the considerable tissue drag that occurs when going through tissue. For this reason, Buhner needles are not threaded before insertion (see the vaginal repair section). The second drawback is that umbilical tape will never dissolve, and producers should have clear discharge instructions about the proper time and method to remove the sutures.

Topical therapy to reduce edema

While all papers reviewing prolapse correction mention methods to alleviate edema in the tissue, more consensus has yet to be made concerning best practices. Topical hyperosmotic solutions made of glycol, salt, or table sugar have been used to draw the fluid out of the tissue.⁴ However, there is a risk that the hyperosmotic materials may further damage the tissue. It is acceptable and often faster to use lubrication and massage to reduce the edema rather than to apply a topical solution.

Additional therapy and follow-up

Depending on the external tissue's condition, the season, and the housing arrangement, treatment should include topical antiseptics and fly spray to help manage skin infection until the suture can be removed. Good client communication will cover the prognosis for recovery and discuss the potentially timely sale of the animal. Finally, clients need to be advised on follow-up care, including additional medications that should be given at home, appropriate milk and meat withdrawal, and the timing of the suture removal.

Rectal prolapses

A rectal prolapse is any protrusion of the rectal mucous membranes through the anus.^{1,6,7} This prolapse is commonly found in a feeder animal 6-24 months of age but can occur in any bovine patient. The 4 grades of rectal prolapse are based on the layers of tissue and the degree of involvement in the prolapse outside the body. There are also 4 different grades of this prolapse based on the severity of the tissue damage.⁶ The latter grading system may be more useful in practice. However, it is sufficient to say that even though the rectal mucosa is very forgiving, less damage is a better prognosis.¹

Causes of a rectal prolapse fall into either too much pushing or insufficient anal tone.⁷ Too much pushing may come from mucosa inflammation (coccidiosis, colitis, diarrhea, prolonged mucosa exposure to cold air), increased abdominal fill, tenesmus from dystocia or vaginal prolapse, dysuria from urolithiasis or cystitis, or excessive estrogen from feed or hormone therapy. Not enough anal tone is typically a result of neurologic

damage from riding injuries to the spine or neoplasia of the spine.⁶ Of the 3 types of prolapses, rectal prolapse has the highest risk of "herd outbreaks" and recurrence, especially if the root problem is not discovered.

After a physical exam is performed to identify the underlying cause of the prolapse, a caudal low-dose epidural analgesia is placed. Tissue is examined for tears, necrosis, and non-viable tissue. The prolapse and the surrounding tissue are cleaned with surgical scrub and water.

If there is a large amount of non-reduceable dead tissue, resection of the dead tissue may be the only option. However, the degree of living mucosa/submucosa that remains and the current size of the animal may exclude this animal as a candidate. If there is not 1 cm of living tissue between the anus and the necrotic material or if this is an extremely young animal, there is an increasing risk of complication over time. While surgical anastomosis or tube amputation can be performed on older animals with ample tissue, it should be reserved for severe prolapses that do not have viable tissue.⁶ For all other rectal prolapses, the rectal mucosa and submucosa can be very forgiving once replaced.

Once the rectal mucosa has been returned to the body cavity, a retention suture will be necessary to hold the tissue in place while the underlying cause is addressed. A purse string suture is placed circumferentially using an S-curve needle with a 3/8" umbilical tape, taking multiple big bites of tissue at least 1" away from the anus. The knot can be tied in a bow dorsally to allow for intermittent loosening if needed for defecation. However, the initial purse string should be tightened enough to allow only small amounts of feces and no prolapse to recur. Published material states that this purse string can be removed in 5 days. Often, producers forget to take the suture out, but this increases the risk of complications, including local infection or stenosis of the anus, because the umbilical tape does not dissolve over time.

Pain management may be warranted, including flunixin meglumine to reduce pain, inflammation, and subsequent tenesmus while the area recovers, as discussed previously in this paper. It may be relevant for the practitioner to have 2 grades of prolapse charges based on severity/time to correct. Producers rewarded financially for bringing in easier prolapses will consider prolapse repair before they become more extensive. Small rectal prolapses cost much less than large, friable, edematous prolapses that may end in amputation because the charge should reflect the amount of time needed to repair them properly.

The prognosis depends on the severity, the success of treatment for an underlying cause, and the relative days on feed remaining. Because most rectal prolapses occur in feeder animals, the goal should be to get the animal to an acceptable weight for slaughter rather than to retain it in the herd as a replacement.

Vaginal prolapse

The definition of a vaginal prolapse focuses on the extent of vaginal tissue outside the labia of the female, along with the possible inclusion of the urinary bladder or cervix. It can happen in any female, gravid or not.

The underlying causes are not entirely understood but can involve a full abdomen (obesity, bloat or a gravid uterus), higher levels of estrogen in late gestation, poor vaginal conformation/stretched ligaments in multiparous cows and certain breeds of

cattle, and occasionally a vaginal polyp or mass.^{4,7,8} Whatever the initial cause, it can start as a minor irritation that progresses to more irritation and can advance to obstruction of the urethra with even more straining.^{7,8}

Regardless of the underlying cause, the severity of the prolapse increases in direct proportion to the time outside the body cavity and inversely with the ambient temperature under 32°F. Because dried vaginal tissue can be challenging to replace successfully, it is worthwhile to encourage producers to bring the cow in during this stage to avoid additional complications and charges. Producers often call the clinic, reporting, “it was out, but it went back in.” They should still come to the clinic.

A physical exam, including body condition score and the risk of rectal prolapse, is always warranted. Most importantly, the veterinarian should determine if she is pregnant because this will affect the method chosen to repair the prolapse. During this exam and repair, it is an excellent time to talk body condition score of the heifers if they are over-conditioned.

Start with a caudal low-dose epidural anesthesia, administered to effect. Once the epidural is administered, the urinary bladder must be emptied by raising the ventral portion of the prolapse and opening the urethra with a gloved finger or a red rubber catheter.¹ The prolapse and the surrounding tissue are cleaned with surgical scrub and water. Replace the prolapse; it may take debridement of dead mucosal tissue or massage. Once again, various topical agents have been described to shrink the edema, but time and massage may have the best outcome.

Once the prolapse is replaced, a suture will be needed to keep it from recurring. Purse string suture going 360 degrees around the vulva using a 12” Buhner needle and double 3/8” umbilical tape can be effective if placed far away from the vulvar lips (2” in an adult bovine.) The veterinarian must get deep into the tissue to purchase a sizeable thick wedge of vestibule tissue.⁴ The procedure starts by driving the UNTHREADED needle starting 2” ventral to the vulvar labia from 6 o’clock to the 12 o’clock position, counter-clockwise and popping it through an incision in the skin at 12 o’clock that is at least 2” dorsal to the vulvar labia. An assistant can thread the doubled umbilical tape through the eye of the needle, leaving at least 1.5 times the length of the vulva in the veterinarian’s left hand (Figure 1). Next, the needle is swiftly drawn ventrally and back out of the original entrance at 6 o’clock (Figure 2). This step results in 2 umbilical tapes side by side from 12- 6 o’clock with the loop dorsally and the tails ventrally. The needle placement is repeated with the unthreaded needle going through the entrance hole at 6 o’clock, clockwise this time, through the vestibule tissue around and out the hole in the skin at 12 o’clock where the doubled umbilical tape is located. Now the assistant can once again thread the eye of the needle with the doubled umbilical tape. Holding the tails at 6 o’clock firmly, the veterinarian withdraws the needle again and brings the rest of the umbilical tape out of the ventral skin hole. The umbilical tape is cinched together until just enough width remains in the vulvar opening to urinate. Then the umbilical tape is tied. Some authors advocate tying in a bow so it can be loosened to check on the progression of calving. Realistically, the accumulating fluids and fecal material make it difficult to untie, and if the animal is pregnant, a different technique should be used.

Figure 1: An assistant can thread the doubled umbilical tape through the eye of the needle, leaving at least 1.5 times the length of the vulva in the veterinarian’s left hand.

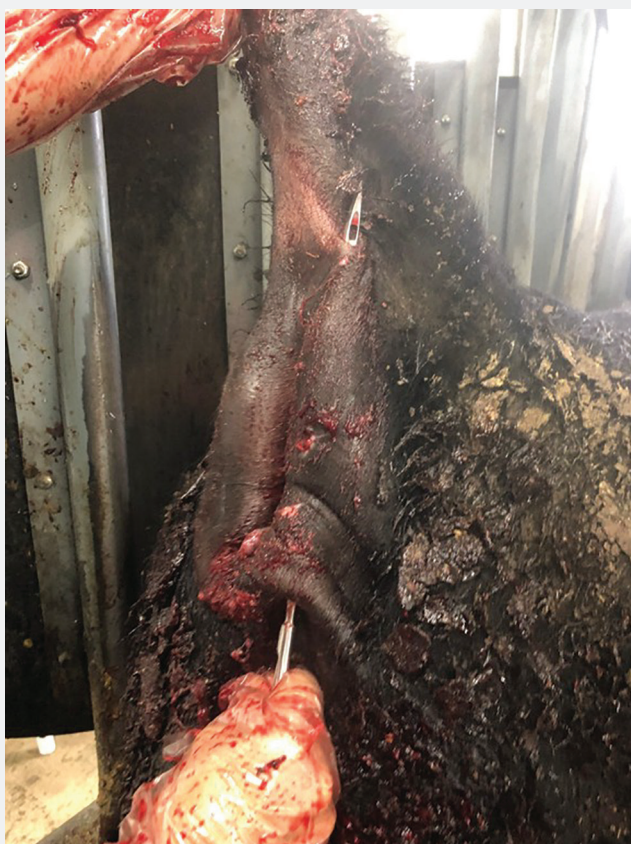

Figure 2: The needle is swiftly drawn ventrally and back out of the original entrance at 6 o’clock.

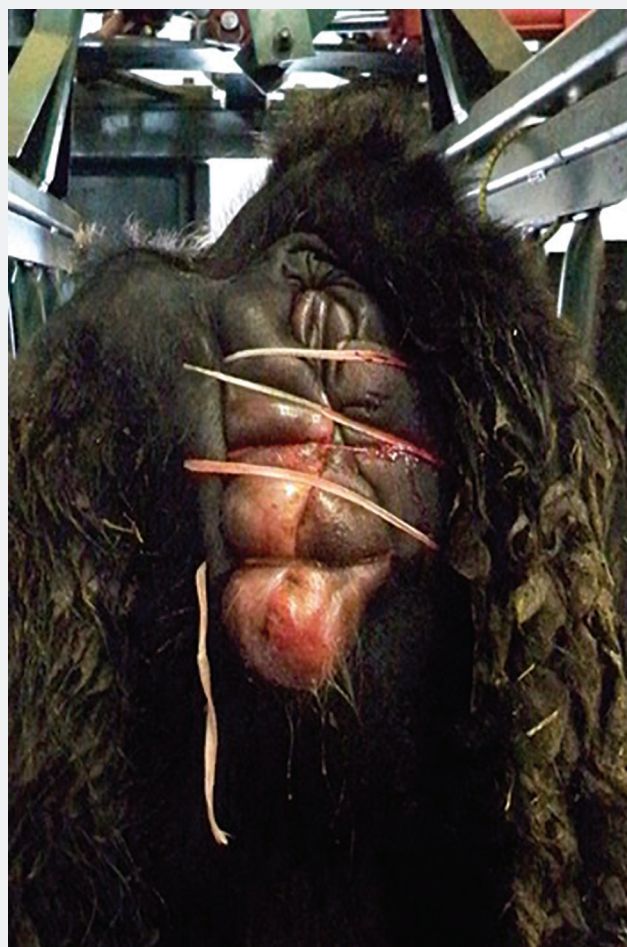


For recurrent prolapses in valuable animals or pregnant females, vaginopexy techniques have been described that use either a large suture or a suture/button combination to tack the dorsolateral vaginal wall through the muscle layers to the exterior hide in the sciatic fossa.⁴ Great care should be taken to avoid the sciatic nerve when placing these types of sutures, and there is a higher risk of complications. Often, the calf should not be delivered vaginally for risk of tearing the repair.

Another option in the gravid female is to place a bootlace/shoe string suture. This technique was developed in theory because part of a waterbag or calf's foot could show through the sutures so the client can recognize that the female is in labor and cut the string. The string is cut during active labor to avoid damage to the dam and increase the possibility of a live calf. For this suture to be successful, it must be placed through the proper tissues. This suture technique is not meant to be a Caslick, and no part of the labia should be incorporated into the suture technique. The suture is placed using a large S-curve needle and 3/8" umbilical tape. Because of tissue drag, it may be necessary to use good pliers for purchase on the needle. The suture pattern should start at least 2" dorsally to the dorsal commissure of the vulvar lips. The pattern must be repeated 5-7 times in 1 to 1 1/2" increments until it has been extended 2" below the bones of the ilium. The hide incorporated in this suture is centered much farther laterally than most veterinarians anticipate and is centered where the short hair of the perineum meets the long hair of the cow's hide. The location of the suture is typically 3-4" lateral to the vulvar opening. Starting in a lateral to medial pattern, a 1.5" bite of the hide is centered where the short hair of the perineum meets the long hair of the hide. This suture bite is in through hide, under subcutaneous tissue deeply, and out through hide exiting at least 2-3" away from the vulvar opening. Cross the vulva at the same height, and repeat the same suture going medially to laterally with the same 1.5" bite of hide centered on the intersection of hair lengths. Cross over the vulva to the right again, moving ventrally 1 1/2". This pattern is repeated until the net result is large bites of hide lateral to the vulva that can be cinched together with this shoestring pattern to create almost a "second wall" of skin over the vulva. The tail from the upper right, where the pattern started, is tied to the final tail on the ventral left, where the pattern ended (Figure 3). The producer is instructed to cut the string anywhere along the shoestring pattern as soon as labor begins. The dam should be identified with a unique tag marker so the client can appreciate the need for intervention from across the yard.

It is worth noting that the chance for the successful delivery of a live calf constantly improves if they have a known delivery date and can induce calving just before that date, so they are present to start cutting sutures. A live calf and cow's prognosis can vastly improve with the shoestring technique and an identifying tag. Nevertheless, there is always a chance that something will die during delivery. Producers should be reminded of this in discharge instructions along with the high chance of this type of prolapse recurring after she calves. This female should be culled from the herd. Follow-up care should be minimal other than antiseptic and fly spray near the suture and being present to cut the suture. A purse string suture can be placed if the prolapse recurs after she calves. Similar to rectal prolapses, there can be different charges for different grades of difficulty when repairing vaginal prolapses.

Figure 3: The tail from the upper right, where the pattern started, is tied to the final tail on the ventral left, where the pattern ended.



Uterine prolapse

This prolapse occurs in a recently calved female and presents as a large prolapse, big as a feed sack/touching the ground, with purple lumps on it.⁶ Literature reports that "both in its appearance and in its pathogenesis, uterine prolapse is quite distinct from cervicovaginal prolapse." However, in the middle of the night, producers need clarification. Most uterine prolapses occur within 6-12 hours after they calve, but some can happen days later, which will complicate their replacement.⁶

The underlying causes include hypocalcemia, an explosive/strong push delivery, and dystocia.^{4,7,8} Personal experience suggests that overcrowding a heifer calving barn to facilitate observation with cameras plays a role in explosive deliveries.

Physical exams should focus on the underlying cause and the cow's overall condition. Because of recent parturition, possible hypocalcemia, or nerve paralysis during dystocia, a veterinarian may find this cow unrestrained in a calving area. While working on the prolapse, special precautions should be taken to restrain the cow to avoid further damage to the uterus or the veterinarian. If the cow is already lying down and can be restrained with a halter, rolling her into sternal recumbency with

her stifles down, and her pelvic limbs back (commonly referred to as “frog-legged”) can facilitate prolapse replacement greatly. However, if the cow stands calmly in a headgate, the prolapse can be replaced while she stands.

A caudal low-dose epidural analgesia should be administered. Next, the veterinarian should remove the placenta, assess for tears in the uterus, and assess the uterine tone. Any tear in the uterine mucosa over 2” in length should be closed using #2 or #3 absorbable suture material in a continuous pattern prior to replacement of the uterus. Conversely, if the uterus “sloshes” when manipulated, there is merit in creating a 3” incision in the near wall of the uterus to look for intestines, blood or a bladder trapped in the everted uterus. Any abdominal viscera trapped must be pushed back into the abdomen before a successful attempt to replace the uterus is made. Simultaneously, if profound damage to the uterus or blood supply and amputation is considered, the uterine arteries and veins can be ligated through this incision before amputation.⁴

Once the uterus has been inspected and cleaned, it needs to be elevated to the level of the ischium bone. Various techniques are described using beach towels, garbage bags, ceramic grates or manual manipulation. Veterinarians’ preferences and the number of assistants available dictate the method used. Common principles include putting the non-gravid horn first, followed by the body of the gravid horn, and finally the tip of the gravid horn. Care should be taken to ensure that the uterus is wholly inverted inside. Techniques vary from infusing warm water into the uterus or manual palpation.^{1, 4, 7} Once the uterus has been replaced, care of the animal should continue, including supportive therapy for metabolic imbalances or shock, nerve paralysis, and pain and infection. Some veterinarians prefer to put a purse string suture around the vaginal opening for 5 days, while others do not. Clients should be given the pros/cons of putting in this suture along with follow-up care instructions. A cow with a uterine prolapse has reduced conception rates compared to herd mates but can breed back successfully. This type of uterine prolapse is not likely to occur again, but ironically, the producer is often the most committed to culling this animal in the author’s experience. It is appropriate to put a temporary ear tag that veterinary staff can identify when checking for pregnancy next fall. It can be removed if she is pregnant and the suture is still there.

References

1. Fubini S, Ducharme N et al. *Farm Animal Surgery*, 2nd ed. St. Louis, MO: Elsevier; 2017.
2. Ismail Z. Epidural analgesia in cattle, buffalo, and camels. *Vet World* 2016; 9(12):1450-1455.
3. Currah J, Hendrick S, Stookey J. The behavioral assessment and alleviation of pain associated with castration in beef calves treated with flunixin meglumine and caudal lidocaine epidural anesthesia with epinephrine. *Can Vet J* 2009; 50(4): 375-382
4. Miesner MD, Anderson DE. Management of uterine and vaginal prolapse in the bovine. *Vet Clin North Am Food Anim Pract* 2008 Jul;24(2):409-19.
5. Compendium of Veterinary Products app <https://mwi.cvp-service.com/product/basic/view/1047536>
6. Anderson DE, Miesner MD. Rectal Prolapse. *Vet Clin North Am Food Anim Pract* 2008 Jul;24(2):403-408.
7. Smith B, Van Metre D, Pusterla N, et al. *Large Animal Internal Medicine*, 6th ed. St. Louis, MO: Elsevier; 2020.
8. Drost M. Complications during gestation in the cow. *Theriogenology* 2007; 68(3):487-491.

