

# Ultrasound beyond reproduction: What I can do in practice

**S. Buczinski**, Dr Vét, DÉS, MSc, Diplomate of the ACVIM

Clinique ambulatoire bovine, Faculté de médecine vétérinaire, Université de Montréal, 3200 rue Sicotte, Saint-Hyacinthe, J2S 2M2 Québec

## Abstract

Ultrasonography is a diagnostic test that is widely used in cattle practice for reproductive tract assessment. Other indications of medical ultrasonography are numerous in cattle. Ultrasound use can easily be extended as part of the evaluation of different medical and surgical conditions in beef cattle practice. The aim of this article is to focus on the current and simplest applications of medical ultrasound that can be easily implemented by the bovine practitioner. Umbilical and lung ultrasonography are used to illustrate on farm use of this important ancillary test.

**Key words:** ultrasound, ultrasonography

## Résumé

L'échographie est un examen complémentaire très répandu en pratique bovine pour le suivi reproducteur. Son utilité peut facilement être étendue dans le cadre de l'évaluation de différentes conditions médicales et chirurgicales chez les bovins de boucherie. Le but de cet article est de focaliser sur les applications courantes et les plus simples à mettre en place par le clinicien en développant notamment son utilisation lors de problèmes ombilicaux et respiratoires.

## Introduction

Ultrasonography is now routinely used for reproduction purposes in dairy and cow-calf operations.<sup>9</sup> Ultrasound not only helps diagnose pregnancy, but also assesses other uterine and ovarian anomalies.<sup>9</sup> Practical monitoring of bull reproductive organs can also be performed using ultrasonography.<sup>11</sup> Beyond reproduction purposes, beef practitioners can use ultrasonography in various clinical situations in the field. The main objective of this presentation is, therefore, to present different clinical indications for using ultrasonography on the farm. We will focus on indications not requiring extra probes, keeping in mind that most veterinary practices are equipped with linear transducers used for pregnancy checking.

The main characteristics of these probes is their high frequency (e.g., > 5 MHz). The high frequency of the probe is associated with good resolution of the image, but absorption of the ultrasound by tissues is important, which gives

a relatively small depth of penetration (e.g., 10 to 12 cm for the deeper structures that can be examined). This must be kept in mind by the practitioner as an important limitation when trying to scan adult animals, especially for abdominal ultrasonography. However, these “reproductive” probes are particularly helpful for most medical and surgical indications in small calves. This is the reason why we will focus more on calves in the rest of the manuscript, keeping in mind practical applications of the diagnostic tests.

## Using Ultrasound for Medical Purpose in Your Practice: How Can You Do It?

As a new diagnostic test that we want to add in practice, it is important first to know the indications for the tests in order for the farmer to see the added value of the test. We do not do diagnostic tests just because it is fancy, but because it helps improve case management, (e.g., individual indication of a more complicated surgery requiring a more complex anesthesia protocol) or for helping make decisions at the herd level (ex: thoracic ultrasonography in calves). Keeping this “added value” in mind, the practitioner can then do a better test selection and put a value on this test which represents the added value (e.g., billing on a time-base plus equipment fees). In general, the total examination time should not exceed 15 minutes and most of time it takes 5 to 10 minutes, including preparation time. We do not do ultrasonography to scan the entire animal, but we do imaging to rule-in/rule-out some specific diagnoses in a specific patient. This “targeted” ultrasound is one of the key elements of this test implementation in practice. Ultrasonography is therefore complementary to a thorough physical examination.

## General Preparation of the Patient and Surface to Scan

Historically, preparation of the bovine patient for transcutaneous ultrasonography required shaving the area of interest, then using coupling gel for improving image quality.<sup>5</sup> This is still the best preparation to do for obtaining high quality images. However, the extra time required for this preparation is generally perceived as a limitation by many veterinary practitioners and farmers. This is especially true when culling decisions are made after the examination, keeping in mind that partially shaved animals can have a decreased value when going to the auction market. For these reasons,

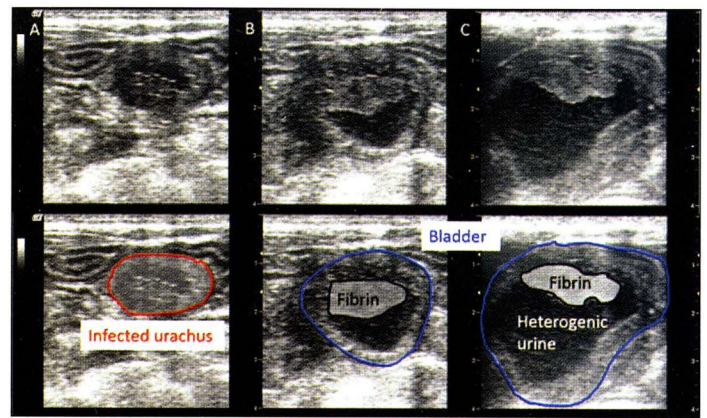
I routinely use only sprayed 70% isopropyl alcohol on the area of interest using a garden sprayer pump. This lessens the total duration time of the examination, and most of time image quality is compatible with clinical use. I shave the area only when it is too dirty or when I want the highest image quality (e.g. for teaching or publication purposes).

### Ultrasonography of Umbilical Structures

Umbilical diseases are commonly seen in calves. Diagnosis of the main umbilical diseases is generally straightforward using only mass and deep abdominal palpation. However, umbilical and abdominal ultrasonography will generally be helpful in 2 particular cases: when examining a large calf ( $\geq 300$  to  $400$  lb;  $135$  to  $180$  kg) to rule-in/rule-out intra-abdominal umbilical structure infection or when suspecting caudal (urachus or arteries) or cranial (vein) infection. In the case of omphalophlebitis, abdominal ultrasonography is helpful to determine if the infected structure ends before reaching the liver, as well as the presence of any liver abscesses. This information is important to discuss when considering surgical procedures (“en bloc” resection vs marsupialization) or for prognosis (poorer prognosis if multiple abscesses are seen). The interest in performing ultrasound in older animals when deep abdominal palpation is not feasible is to assess the size and extent of the infection (e.g. infected urachus or artery) for planning an adequate anesthetic protocol, depending on the anticipated complexity of the intervention.

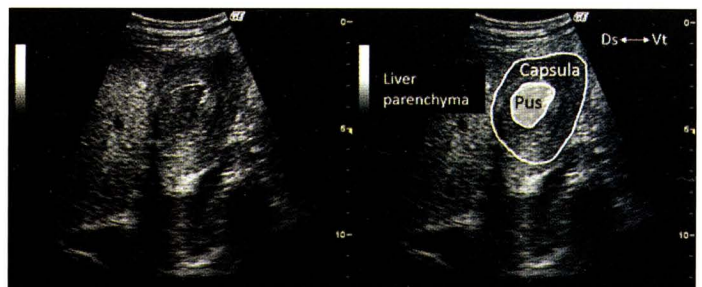The abdomen can be shaved in animals with dirty hair. The linear or sectorial probe can be used, depending on the size of the animal. A high-frequency linear probe  $\geq 5$  MHz is used for young animals when the required depth of visualization is less than  $10$  to  $15$  cm. A probe  $< 5$  MHz is required for examining larger animals ( $\geq 300$  to  $400$  lb;  $135$  to  $180$  kg). The examination should be done based on palpation findings and clinical suspicion, and generally starts by applying the probe to the umbilicus perpendicular to the animal’s vertebral column. The probe is then moved caudally to observe any infected abnormal structures in cross-section (urachus or arteries), the extent of infection, and size of the infected remnants. Infected structures always have the same general aspects, including thickened wall and heterogenic content (Figure 1). The relation between the bladder and infected remnant is important to distinguish urachal infection (more common) vs artery infection. Large arterial abscesses appear lateral to the bladder, and preoperative diagnosis allows anticipation of a more complicated surgery, decreasing the possibility of “en bloc” resection vs abscess marsupialization. In this particular case, ultrasonography is helpful to more properly inform the owner before doing the surgery.

When suspecting omphalophlebitis, the probe is then placed cranial to the umbilicus and moved dorso-laterally on the right to follow the infected organ until the liver parenchyma is observed (Figure 2). It is important to know if



**Figure 1.** Cross-sectional aspect of infected urachus and associated cystitis in a 40 day-old calf.

The left image is showing typical aspect of infected urachal remnant with a circular shape and heterogenic content. When moving caudally following the infected urachus the urinary bladder is seen with heterogenic content and a fibrin clot.



**Figure 2.** Liver abscessation associated with omphalophlebitis in a 30 day-old calf.

A cavitory lesion with thick wall and heterogenic content is observed in the peripheral part of the liver.

infection extends to the liver to decide whether an “en-bloc resection” is possible or not. Marsupialization in cases of infection reaching the liver generally requires a higher level of care, and therefore prevision of this surgery is important. Evaluation of liver parenchyma is also helpful to detect possible abscesses, which are generally associated with a poorer prognosis.

In conclusion, umbilical diseases abdominal ultrasonography is helpful to determine the extension of intra-abdominal infection before surgical exploration. Ultrasonography can therefore be used especially when the owner is reluctant to perform a blind surgery if the case management is complicated. In this situation, the veterinarian can give important information to the owner at a lower cost than laparotomy. Early culling decisions can be made depending on the relative surgery and postoperative care costs vs the value of the calf and expected prognosis.



## Ultrasonography of the Thorax

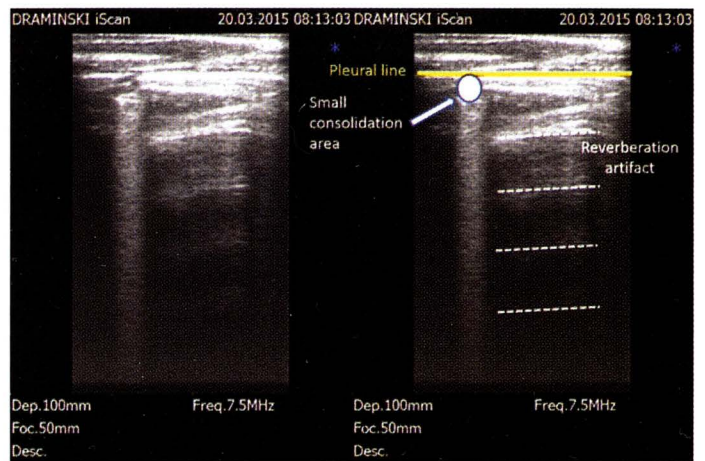
Ultrasonography of the thorax is certainly an area where a lot of practical information was gathered especially in dairy calves, as recently reviewed.<sup>15</sup> The data on beef calves are contradictory. In a commercial feedlot study in Western Canada, a focused unilateral examination with a sectorial low-frequency probe did not show any impact of ultrasonographic lung lesions and various prognostic outcomes.<sup>1</sup> By contrast, a case-control study in a trial documenting evolution of bronchial lavage in naturally occurring respiratory disease during the early feeding period showed that lung consolidation was associated with the risk of dying during the study period I,<sup>16</sup> as previously found in dairy calves.<sup>8</sup> The main difference between both studies beyond their experimental design was the technique of performing the ultrasonographic examination.

A systematic bilateral scanning of the whole pleural area is required to detect lung lesions. Scanning only a side of the thorax may lead to under-detection of a significant number of lesions.<sup>8,16</sup> This scanning is performed after spraying the intercostal spaces with alcohol without clipping. The available scanning area is generally limited to the lung surface caudal to the heart in large beef calves. In small calves, the cranial part of the lung can also be scanned by applying the probe cranial to the heart and gently pushing under the right forelimb.<sup>15</sup>

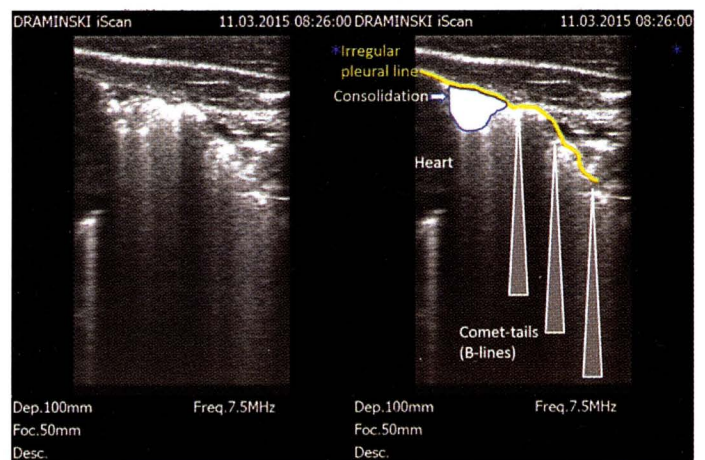
The learning curve is fast after recognizing the typical findings in a normal lung area. The lung parenchyma is filled with air in the alveolar space. For this reason, it is impossible to see the normal aerated lung, because the total ultrasound beam is reflected back to the transducer at the surface of the parenchyma. The practical implication of this phenomenon is a hyperechoic pleural line representing the visceral and parietal pleura. The operator can also see the sliding movement due to the calves' breathing movements. A reverberation artefact is also frequently seen, and represents a phenomenon where part of the ultrasound waves reflected to the transducer are coming back to the pleural surface, and so on. This will give the typical aspect of what is called A-lines<sup>13</sup> giving horizontal echoic lines (i.e., parallel to the pleural line) with decreased echogenicity (Figure 3).

When inflammation and infection are present, several anomalies will be observed and disrupt the typical horizontal line aspect of the space deeper to the pleural line. Irregularity and thickening of the visceral pleura can be observed and will be detected by an irregular pleural line and the presence of "comet-tail" (also called B-lines) artifact (Figure 4). These artifacts give a "fuzzy" aspect of the part of the screen below the pleural line. They should not be confused with lung consolidation.

The ultrasonographic lung consolidation is the main anomaly of interest when doing thoracic ultrasonography. The term "ultrasonographic consolidation" is not similar with macroscopic lung consolidation defined in necropsy. Ultrasonographic lung consolidation is observed when the



**Figure 3.** Normal and abnormal ultrasonographic lung ultrasound. The normal lung is characterized by reverberation artifacts due to gas content of the alveolar space contiguous to the pleura (dotted lines). A small heterogenous consolidation area is also observed.



**Figure 4.** Consolidation and comet-tails artifacts. This ultrasonogram obtained close to the cardiac area is characterized by an irregular pleural line, the presence of comet-tails artifacts (B-lines) and a small spot of consolidation.

alveolar space contiguous to the pleural line is filled by either liquid, cells or pus or when air has been pushed away from this area in cases of atelectasia. Whatever the cause of consolidation, if lung parenchyma is observed when doing ultrasound, this means that a part of the lung can not be used for gas exchanges. This may potentially explain why growth may be affected in this situation.

Lung consolidation is a proxy of ongoing or previous pneumonia in cattle. Other causes of ultrasonographic consolidation, such as neoplasm or non-infectious atelectasia, are uncommon. Ultrasonography has been used both as a calf- and herd-level tool in dairy cattle.<sup>7,15</sup> In cow-calf operations, data are still lacking but potential applications of thoracic ultrasound are assessment of respiratory health and farmer

detection capacity, as well as helping in the diagnosis when clinical signs are not obvious. Thoracic ultrasonography should not be a decision tool for treating a calf. In foals, treatment of animals based only on lung lesions associated with *Rhodococcus equi* infection detected by ultrasonography did not improve them vs placebo-treated foals in a randomized controlled trial.<sup>18</sup> Such information is not available for the moment in beef calves, but it should be noted that ultrasonographic consolidation may be non-active lung lesions where antimicrobial treatment is useless. Systematic screening of a herd, however, may be useful for having an objective measure of respiratory disease and may serve as a metric for improvement when controlling for specific herd risk factors.<sup>7</sup> In dairy calves, lung consolidation has been associated with various negative production outcomes, including decreased survival before first calving and decreased milk production.<sup>2,10,17</sup> Such information is still lacking for beef replacement heifers, but may help to determine animals at higher risk of not being successfully bred.

### Other Applications and Conclusions

The 2 major practical applications of ultrasonography with the linear probe used for reproduction purpose have been presented. These applications can be rapidly applied without specific equipment investment. However, ultrasonography may potentially be helpful for a lot of soft-tissue problems, such as gastrointestinal diseases<sup>3,4</sup> and cardiovascular diseases.<sup>6,14</sup> Diagnosis of musculoskeletal problems<sup>12</sup> have been mentioned, but are out of the scope of this review. One of the major advantages of ultrasound is that it can be done calf or cow-side, and therefore may be very visual for the owner. Moreover, because it is performed rapidly when the operator is proficient with the technique, it is helpful to confirm or rule out different diseases, which can serve as a more efficient way to target a treatment based on the updated disease information. In doubtful cases, the veterinarian is encouraged to screen herd-mates, use previously published literature, and to follow wet labs and/or seminars on extragenital use of ultrasound. Finally, this ancillary test is also a good way to improve the image of the bovine veterinarian as a professional of individual health, using imaging to tailor medical or surgical treatments.

### References

1. Abutarbush SM, Pollock CM, Wildman BK, Perrett T, Schunicht OC, Fenton RK, Hannon SJ, Vogstad AR, Jim GK, Booker CW. Evaluation of the diagnostic and prognostic utility of ultrasonography at first diagnosis of presumptive bovine respiratory disease. *Can J Vet Res* 2012; 76:23-32.
2. Adams EA, Buczinski S. Short communication: Ultrasonographic assessment of lung consolidation postweaning and survival to the first lactation in dairy heifers. *J Dairy Sci* 2016; 99:1465-1470.
3. Braun U. Ultrasonographic Examination of the reticulum, rumen, omasum, abomasum, and liver in calves. *Vet Clin North Am Food Anim Pract* 2016; 32:85-107.
4. Braun U. Ultrasonography of the gastrointestinal tract in cattle. *Vet Clin North Am Food Anim Pract* 2009; 25:567-590.
5. Braun U, Gotz M. Ultrasonography of the reticulum in cows. *Am J Vet Res* 1994; 55:325-332.
6. Buczinski S. Cardiovascular ultrasonography in cattle. *Vet Clin North Am Food Anim Pract* 2009; 25:611-632.
7. Buczinski S, Borris ME, Dubuc J. Herd-level prevalence of the ultrasonographic lung lesions associated with bovine respiratory disease and related environmental risk factors. *J Dairy Sci* 2018; 101:2423-2432.
8. Buczinski S, Forté G, Francoz D, Bélanger AM. Comparison of thoracic auscultation, clinical score, and ultrasonography as indicators of bovine respiratory disease in preweaned dairy calves. *J Vet Intern Med* 2014; 28:234-242.
9. DesCôteaux L, Colloton J, Gnemmi G. In: Practical atlas of ruminant and camelid reproductive ultrasonography. DesCôteaux L, Colloton J, Gnemmi G, eds. Hoboken: Wiley-Blackwell, 2009; 83-86.
10. Dunn TR, Ollivett TL, Renaud DL, Leslie KE, LeBlanc SJ, Duffield TF, Kelton DF. The effect of lung consolidation, as determined by ultrasonography, on first-lactation milk production in Holstein dairy calves. *J Dairy Sci* 2018; 101:5404-5410.
11. Gnemmi G, Lefebvre RC. Ultrasound imaging of the bull reproductive tract: An important field of expertise for veterinarians. *Vet Clin North Am Food Anim Pract* 2009; 25:767-779.
12. Kofler J. Ultrasonography as a diagnostic aid in bovine musculoskeletal disorders. *Vet Clin North Am Food Anim Pract* 2009; 25:687-731.
13. Lichtenstein DA, Meziere GA. Relevance of lung ultrasound in the diagnosis of acute respiratory failure: The BLUE protocol. *Chest* 2008; 134:117-125.
14. Mitchell KJ, Schwarzwald CC. Echocardiography for the assessment of congenital heart defects in calves. *Vet Clin North Am Food Anim Pract* 2016; 32:37-54.
15. Ollivett TL, Buczinski S. On-farm use of ultrasonography for bovine respiratory disease. *Vet Clin North Am Food Anim Pract* 2016; 32:19-35.
16. Rademacher RM, Buczinski S, Edmonds M, Tripp HT, Johnson E. Systematic thoracic ultrasonography in acute bovine respiratory disease of feedlot steers: impact of lung consolidation on diagnosis and prognosis in a case-control study. *Bov Pract* 2014; 41:1-10.
17. Teixeira AG, McArt JA, Bicalho RC. Thoracic ultrasound assessment of lung consolidation at weaning in Holstein dairy heifers: Reproductive performance and survival. *J Dairy Sci* 2017; 100:2985-2991.
18. Venner M, Astheimer K, Lämmer M, Giguère S. Efficacy of mass antimicrobial treatment of foals with subclinical pulmonary abscesses associated with *Rhodococcus equi*. *J Vet Intern Med* 2013; 27:171-176.