

No Loose Parts Necropsy Procedure for the Feedyard

Dee Griffin, DVM, MS, University of Nebraska Great Plains Veterinary Educational Center, Clay Center, NE 68933

Abstract

The necropsy technique outlined accomplishes three important objectives: 1) examination of all body systems, including the CNS, with the speed required to complete the procedure in less than 30 minutes; 2) targets identification of infectious disease in body systems through lymph node pathology; and 3) minimizes hide damage and detached body parts, both of which create serious problems for rendering companies.

Introduction

It has been said, the most important animal in a feedlot maybe the one that dies. While this seems inappropriate, no doubt valuable management information can be obtained from the thorough examination of each animal that dies in a beef feedlot.

Important Note: If animals are headed for rendering they must be safe for byproduct consumption. Three classifications of cattle must not be allowed to go to rendering, and should be identified so that a renderer does not mistakenly pick them up. These include: Cattle treated or euthanized with a drug that creates a residue (heat stable antibiotics, barbiturates, etc), bovine spongiform encephalitis (BSE) or Rabies suspects, and cattle that die from a chemical toxicosis. Cattle in this category should be buried on the premise.

What is Different About the Procedure Outlined in this Paper and the Procedure Taught in Most Veterinary Colleges?

This paper offers four changes that will improve the efficiency of feedlot necropsies. First, the procedure is designed to allow an "assembly line" (or un-assembly line) flow. Second, the procedure is designed to minimize hide damage and loose or detached tissues that create a disposal problem for the feedlot. Third, the procedure is designed to make it easy to examine the central nervous system of each animal. Fourth, the procedures focus on tracing system lymph nodes for rapid identification of systems affected by infectious disease (See Figures 1 and 2). Fifth, a necropsy findings check-off form is included to make it easy to

record observations and incorporate them into a necropsy database.

Equipment

Knives

Never leave home without several sharp knives. While there is considerable individual preference, a stiff bladed knife six inches long is undoubtedly safer than a flexible boning knife for necropsies on cattle over 600 pounds. Stiff boning and sheep skinning knives are my preferred knife styles. It is important to have several, and all must be sharp.

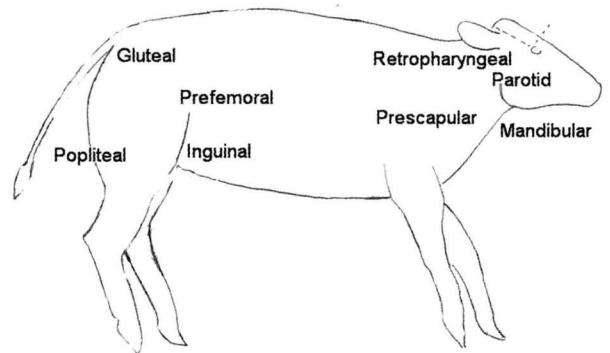


Figure 1.

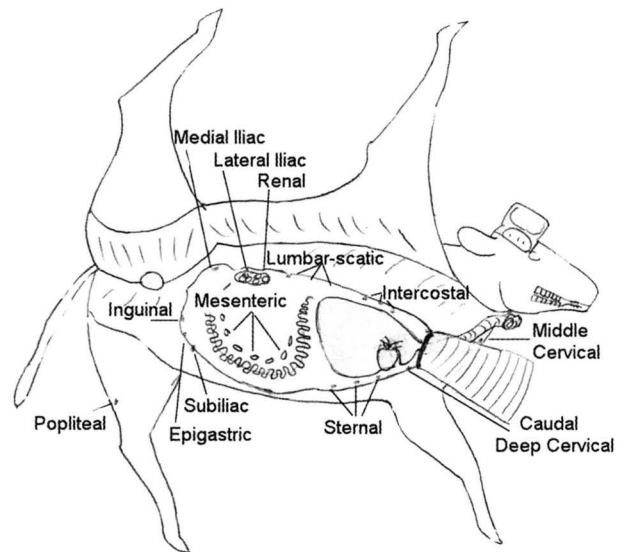


Figure 2.

Ax

One, 32 to 40 ounce sharp single bit ax is essential for examination of the brain. I use a 36 ounce "boy's" ax. Double bladed axes are unstable and do not provide a blunt side for breaking the cut edges of the skull away from the brain. The blade of a 48 ounce ax is too large to make fine cuts along the upper edge of the cranium.

Steels

Two blade straightening steels, one fine (smooth) and one medium steel. Steels should be used to straighten the fine edge of a sharp blade.

File

One flat bastard file for sharpening the ax.

Fine emery cloth

A small oiled strip of fine emery cloth for dressing the surface of the steels.

Sterile syringes and needles

10 cc syringes and 20-gage, 1.5-inch needles for collecting needle aspirates and for inoculating agar plates.

Butane lighter

Use a butane lighter for sterilizing aspiration needle before using needle to streak agar plate.

Other standard veterinary necropsy equipment and supplies include

Leak proof sterile tissue sample bags, 10% formaldehyde, and personal protection clothing.

Sharp knives

Sharp knives take a lot of the work out of necropsies. Veterinarians spend more money trying to get & keep sharp knives than any other gross diagnostic item. Keeping a sharp knife is not simple, but it is not hard. The following sharp knife keys list:

1. Have lots of sharp knives with you (cheaper to buy knives in boxes of 6). Knife suppliers include: Hantover 800-821-2227 or KOCH 800-456-5624. Select stiff bladed boning or skinning knives. A sheep skinner is my favorite.
2. Use a sharp ax to make your skin cuts. It will save your knife blade edge. A flat bastard file works great for keeping the ax sharp. Get a REAL sharpening tool such as Flap Wheel Knife Sharpener or a WEN Wet Stone Sharpener for your knives. Flap sanders cost about \$250. The WEN sharpener costs about \$40. Both will eat knife blades, but they will be sharp. TIP: Keep a thick blade angle (approximately 15 de-

grees) and work the final edge to approximately 20 degrees. Another option is to let someone else keep your knives sharp.

3. Use the steel properly. Steels straighten blades, NOT SHARPEN them.

The Procedure

As tissues are collected they are placed in the foreleg reflection. Do not cut your samples more than one half inch thick. All cultures are collected by aspirate.

Using the ax, set the skin pattern by cutting the mid-line from the neck, along the abdomen, and behind the rear leg (Figure 3).

Use the ax to pattern the cut for the head. Make two cuts behind the poll, two cuts across the face at the lateral palpebral fissure, and two cuts upper lateral skull connecting the face and poll cuts (Figure 3).

Cut the skin free along the skull cuts. Using the blunt side of the ax blade, break the bones away from the skull. Cut dura and lift the brain out (Figure 3).

Next, start skinning front to back approximately a third up the side. When you get to the rear leg, cut through the muscles until the hip joint is disarticulated and the leg will remain reflected (Figure 4).

Reflect the foreleg, continuing to skin the abdomen (Figure 5).

Cut along the inside of the mouth, exposing the molars to age the animal [Age: 1st (7-12), 2nd (12-18), 3rd (24-36)]. Lift out the larynx and trachea, and examine the esophagus, larynx and trachea (Figure 6).

Reflect the abdominal musculature.

Using the ax, cut along the distal costal junction. I sometimes use the ax to cut the ribs away from the spine. DO NOT REMOVE THE FIRST RIB. The first rib will hold the pluck in place, and the reflected ribs will serve as a table for the pluck during examination (Figure 6).

Cut the pluck free & reflect over the first rib (Figure 6). Examine the lung, heart, etc.

Next cut the omentum free, and lift the intestines

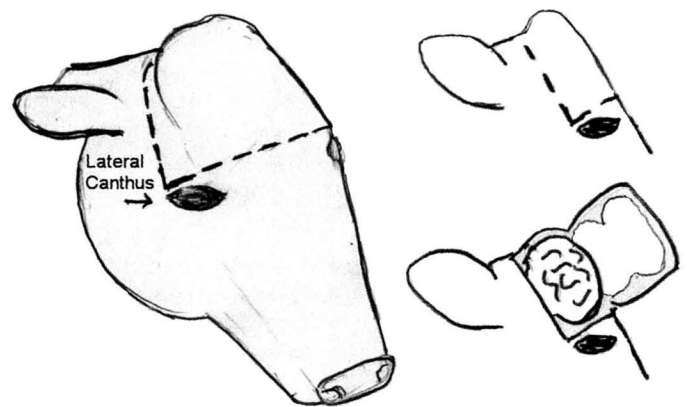


Figure 3.

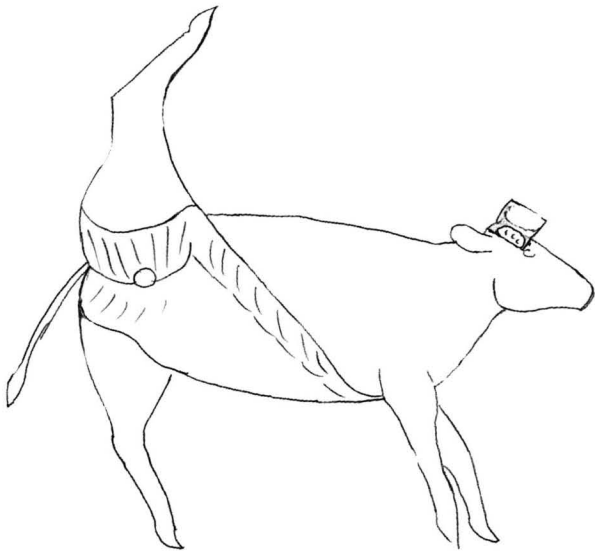


Figure 4.

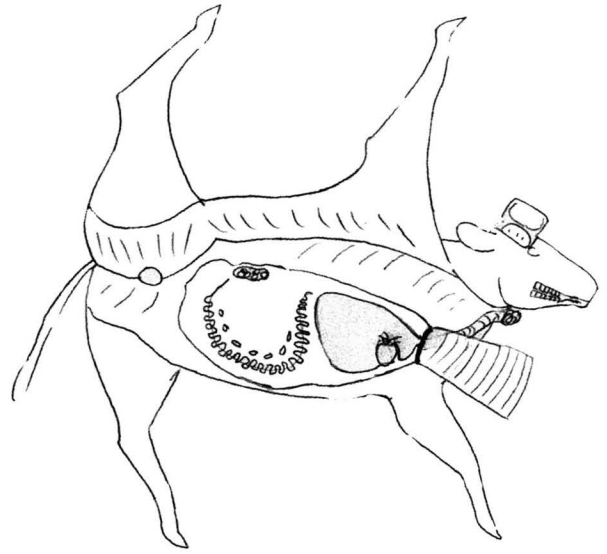


Figure 6.

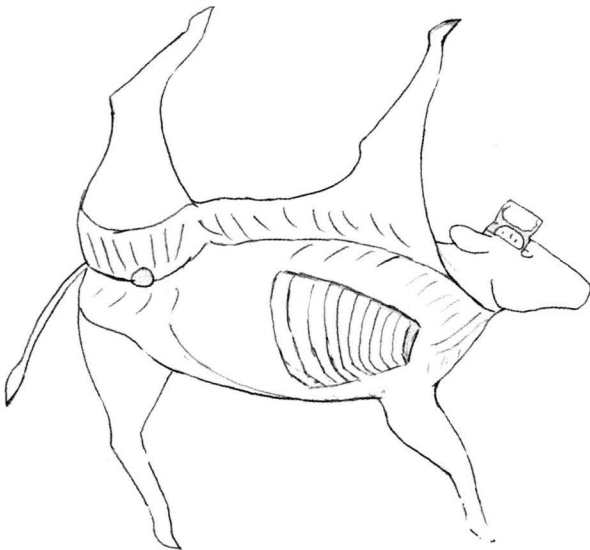


Figure 5.

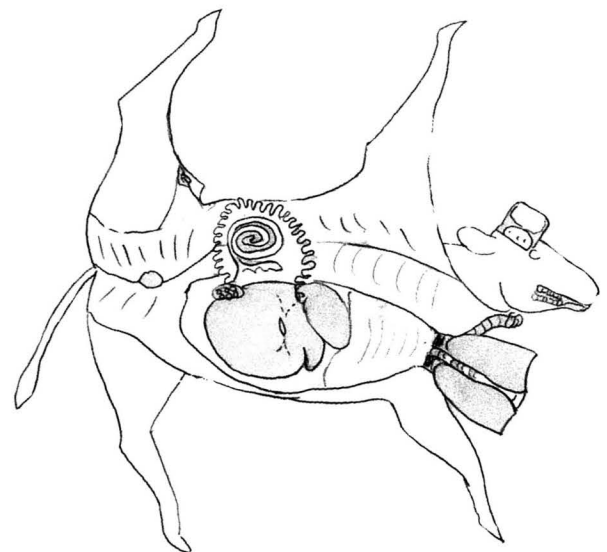


Figure 7.

out and fan over the abdominal cavity (Figure 6). Examine the small intestine and associated lymph nodes.

Next flip the intestines over to examine the large intestine (Figure 7).

Cut through the surface of the kidney, lift out but do not remove. Examine bladder and rectum.

Examine the gall bladder and bile ducts. Cut the liver free from the diaphragm and reflect back over the rumen. Make 10 to 15 cuts in the liver and closely examine both the surface and cuts in the liver.

Examine spleen by reaching under the edge of the rumen. Cut small hole, approximately 12 inches, in the anterior rumen. Pull pillars through the hole and examine.

Examine the hock joint. Cut along the anterior medial aspect of the tibia exposing the fibularis muscle. Cut across the belly and reflect across the cavity of the tarso-crural joint.

The Form

A check-off form (see next page) will improve the efficiency, accuracy and utility of data collection. You may feel uncomfortable when you first start to use a check-off form, but the advantage gained for data analysis is worth making a check-off form part of your necropsy technique.

Long Form

Date: _____ Animal & Pen ID: _____ HISTO - BACT-VIRO-TOX
 Found dead / Euth If found dead, approx time found: _____ PM interval (1-24 hrs)
 Pen where died: recev ____, home ____, hosp ____, recov ____, buller ____, alley ____, Last time known alive: _____
 Location in pen where found: feedbunk ____, waterer ____, side ____, back ____, corner ____, middle _____
 Weight: (<4,4-6,6-8,8-10,>10) Sex(S,H,B) Breed(B,E,Z,D) Heat-Cold-Shipping-Weaning-Dust-Rain-Mud
 H temp: <30,30,40,50,60,70,80,90,>90. L temp: <0,0,10,20,30,40,50,60,70.
 Days on last ration: <7, >7, >30 days DOF: (1)0-7,(2)8-30,(3)31-60,(4)61-90,(5)91-150,(6)>150d
 Ration: WC, RC, HMC, AH, CS, SBM, LP, F, Bf // Ration meds: A,O,D,R,T,L,C,M (g/t _____)
 Vacc: IBR,PI3,BVD,BRSV,HS,PAST,C4,C7, (Prec/Proc/Revac) (MLV,K) Previously Sick (N -Y: <30or>30 days)
 Diagnosis & Treatment _____ AB: (SUL, TYL, OTC, AMP, PEN, ERY, NAX, SP, MICT, NUFL) // MM:(Y-N)

NGL-NE	GENERAL EXAM	NGL-NE	LUNG/PLEURA: bi / un	NGL-NE	LYMPH NODES
	Auto(None-Slight-Stale-Sev-Rot)		Pleural effusion/fibrin		Head-Cerv-Pulm-Mesenteric-Colon
	Bloated-Thin		Collapsed		Edema-Hemorrhage-Inflamed-Swol
	Flesh (T, N, O)		Congestion	NGL-NE	Kidney (Lf/Rt)
NGL-NE	SKIN		Septal edema		Pale / Dark
	Alopecia-Dermatitis		Emphysema		Contracted
	General-Head-Trunk-Extremi		Consolidation		Swollen
	NOSE: Dry-Crusty		Old Adhesions		Cortical_scars-Streaks
	HEAD-SINUS': Injury-Infection		Abscesses		Infarcts
	SUB Q: Hemorrhage-Icteric-Edema		Healed		Rough_cortical_surface
	FEET(Fore-Hind-Medial-Lateral):		%Affected(<1/3,1/3-2/3,>2/3)		Petechia
	MAMMARY GLAND: Infected		Age(peria-acute-suba-chr)		Dilated/Abscessed
		NGL-NE	INTESTINE		Mushy (with / with out)
NGL-NE	Oral Cavity		Duodenum-Jejunum-Ilium		Bladder ecchymosis
	Tongue (hair sore)		Gas (none,segmental ,throughout)		Urine; (Normal,Pale,Dark,Hemo)
	Pharynx / tonsil / injury		Cecum/colon		Ureters: dilated-Exudate-Hemo
	Age: 1(7-12) 2(12-18) 3(24-36)		Content (white-yellow-red-brown)		Urethra: dilated-Exudate-Hemo
NGL-NE	NECK		Casts-Edema-Hemorrhage		Inflamed-Ruptured-Stones
	Veins distended		Obstructed-Inflamed-Parasites	NGL-NE	Reproductive
	Perivascular injection		Surface color (normal/red/green)		Infected
	Congestion		Rectum		pregnant (1-9)
	Emphysema	NGL-NE	MESENTERY-OMENTUM-PERIT	NGL-NE	RUMEN RETICULUM-OMASUM:
	Petechiae/ecchymosis		Lymph nodes		Adhesion -Hemorrhage
NGL-NE	ESOPHAGUS		Edema, Hemorrhage, Inflamed,		Free Gas
	Congestion		Parasites		Froth / porridge
	Ulcers	NGL-NE	LIVER-PANCREAS		pH (x.xx)
	Parasite		Jaundiced		Serosa (pale / dark) Adhesions
NGL-NE	TRACHEA		Congested		Clumping (mod, ext)
	Mural reddening		Nutmeg		Erosions - Ulcers- Hemo-Spots
	Pseudomembrane		Surface spots / Scars		Submucosal color (pale/pink/dkred)
	Laryngeal necrosis		Abscess	NGL-NE	ABOMASUM:
	Edema@thoracis inlet		Uniformly pale (autolysis)		Edema-Hemorrhage
	H/E dorsalmembrane	NGL-NE	GALLBLADDER Casts-Bileducts-Flukes		Erosions-Ulcers (pp, lin, irr)
	Froth		Casts-Bileducts-Flukes		Spots-Impaction-Parasites
NGL-NE	HEART		Size (normal / enlarged)	NGL-NE	SPLEEN
	Pericardial Inflammation (Tram-Y/N)	NGL-NE	Adrenal glands		Swollen / Contracted
	Pericardial Effusion	NGL-NE	MUSCLES	NGL-NE	LONG BONES-JTS-T/L-SPINE
	Epicardial Petechia / ecchomosis		Cervical-ForeLeg-Trunk-HindLeg-E		Cervical-ForeLeg-Trunk-HindLeg-Ext
	Endocardial Petechial/ecchomosis		Hemo-Infected/Infila-Pale		Injury-Infected
	Myocardial Necrosis		Injection	NGL-NE	BRAIN-PIT-SPCORD-EYES-EARS CORD-
	Valve lesions		Injury		Abscess-Edema-Hemorrhage
					Infected-Inflamed-Injury-Necrosis

ETIOLOGY:	C=Circulatory	G=Genetic	I=Infectious	M=Metabolic	N=Neoplasia	P=Parasitic	T=Trauma	Tx=Toxic	U=Unknown
System:	Gen Body	Skin/SubQ	Mus / Skel	Resp	Circ/Hem/Lym	Digestive	Urinary	Repro	Nervous
Rank Sys & Etio:									

© Copyright American Association of Bovine Practitioners; open access distribution.