

# General Session

Dr. Robert Darlington, *Presiding*

---

## THE CLINICAL EXAMINATION OF CATTLE Part 1: The Examination of the Individual Animal

**O. M. Radostits, D.V.M.**

*Department of Veterinary Clinical Studies, Western College of Veterinary Medicine, University of Saskatchewan, Saskatoon, Saskatchewan, Canada*

The most common reason for the clinical examination of the individual animal is to make a clinical diagnosis so that effective treatment can be given and control procedures instituted.

The clinical examination of the individual animal must be rapid, complete, economical and highly accurate. However, a thorough examination may take considerable time and re-examination of an individual animal may be necessary in order to make a diagnosis. **“More mistakes are made for not looking than for not knowing”.**

The individual cow is relatively easy to examine because the body systems which are most commonly affected are easily accessible. The digestive tract, the reproductive organs, the urinary tract, the musculoskeletal system, the respiratory tract and the skin can be easily examined in the field. In recumbent cattle, a complete reliable neurological examination may be difficult, but a sufficient examination is possible in most cases.

**This paper outlines a systematic method of clinical examination which will yield the most useful information necessary to make an etiologically specific diagnosis. The challenge is to examine a sick cow and detect and interpret the clinically significant abnormalities and to make a diagnosis. Some details are provided on the examination of some selected body systems.**

The problems associated with the clinical examination and making a diagnosis include:

1. *Preconceived ideas about the diagnosis.* Experienced veterinarians tend to make a diagnosis based on the recognition of a few reliable epidemiological and clinical findings.

2. *Incomplete history and incomplete clinical examination.* An incomplete history and failure to detect the

abnormalities which are not readily obvious are major causes of misdiagnosis.

3. *Incorrect interpretation of the clinical findings.* A knowledge of the pathophysiology of systemic medicine is necessary to accurately interpret abnormalities.

4. *Failure to consider all of the diagnostic possibilities.* This is becoming a major problem because of the ever increasing number of possibilities generated by the recognition and description of diseases.

*When diagnosis is not obvious, a systematic clinical examination is necessary in order to achieve a high degree of accuracy.*

A complete clinical examination consists of four parts:

1. *Taking the History.* On the initial visit the history taken should be as complete as possible. Incomplete histories commonly lead to misinterpretation of clinical findings.

2. *Examination of the Environment* (including the remainder of the herd). The immediate environment of the animal may provide clues about the diagnosis.

3. *The Actual Clinical Examination.* The clinical examination consists of a general body inspection and a detailed examination of each body system.

4. *The Use of the Laboratory.* The laboratory should be used as much as necessary to support or exclude the tentative clinical diagnoses. The laboratory will often provide important information which will direct the veterinarian to re-examine certain body systems in order to detect significant abnormalities which were not obvious on initial examination of the animal. An example is the presence of a leucopenia, neutropenia and a degenerative left shift in a cow with sudden anorexia due to peritonitis which is not readily obvious,

## A Complete Clinical Examination

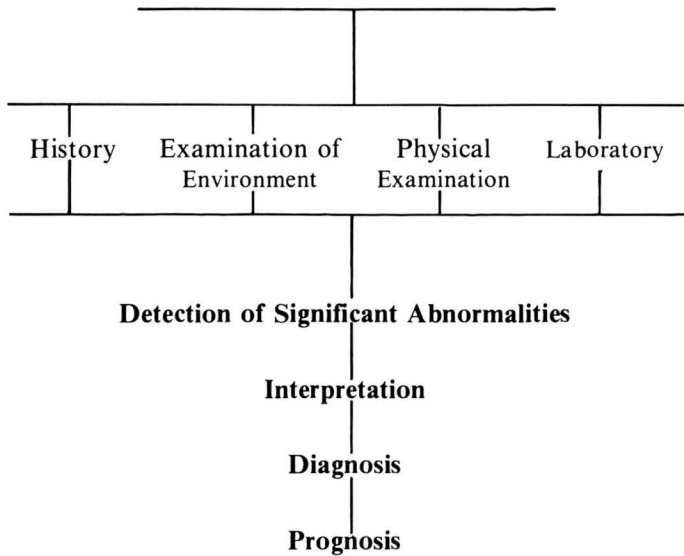
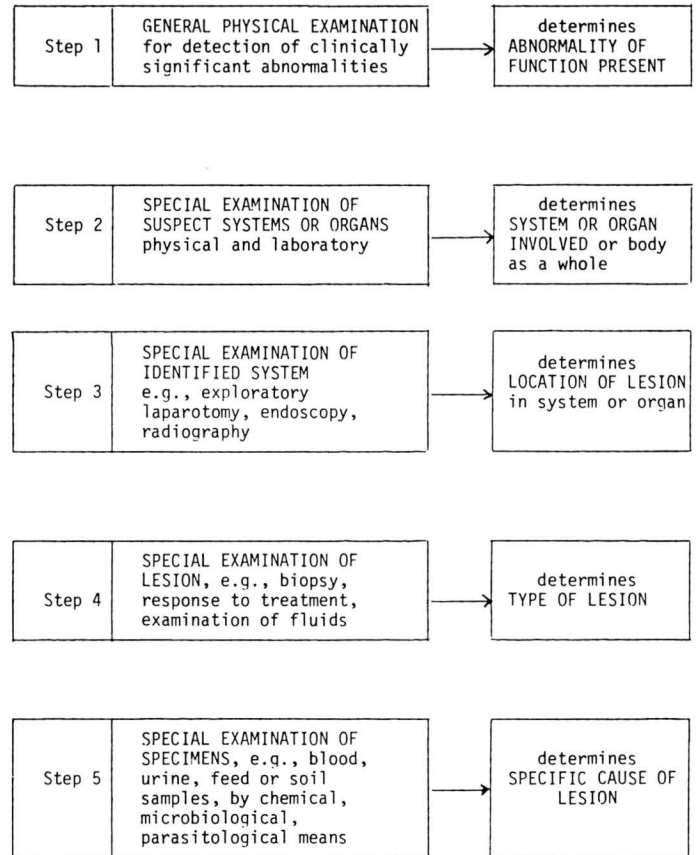


Figure 1. Clinical Examination and Making a Diagnosis



The steps involved in the clinical examination of an animal in order to make a diagnosis appear in Figure 1. An example follows:

1. *Detection of the clinically significant abnormalities of function present in the animal.* Example: Dyspnea, toxemia and fever in a recently weaned beef calf 6 months of age.
2. *Determination of the body system or body as a whole which is involved.* Example: Dyspnea in the weaned calf suggests involvement of the respiratory tract.
3. *Determination of the location of the lesion within the body system.* Example: The presence of abnormal lung sounds on auscultation of the thorax indicates the presence of lesions in the lung.
4. *Determination of the type of lesion.* Example: The fever, toxemia and moist rales indicate an acute bacterial bronchopneumonia.
5. *Determination of the specific cause of the lesion.* Example: Isolation of *Past. hemolytica* by sampling the secretions of the nasal cavities and transtracheal aspiration reveals the specific cause of the pneumonia.

An etiologically specific diagnosis is the net result of the consideration of many diagnostic possibilities. This is illustrated in Figure 2. For example, there are many different causes of dyspnea in cattle. A careful clinical examination is necessary to detect other possible abnormalities which may indicate that the dyspnea is due to causes other than disease of the respiratory tract.

The equipment needed for a complete field clinical examination is not expensive and includes the following:

Thermometer	Rectal palpation sleeve
Stethoscope	Strip cut
Flashlight	CMT and paddle
Pleximeter and plexor	Hoof knife
Oral speculum	Ophthalmoscope

Stomach tube and pump	Needles and syringes for paracentesis
Wide range (1-11) pH paper	Spinal needles
Lalstix (for urinalysis)	Hemetest tablets

*The Methods of Clinical Examination* include the following:

- Audiovisual Inspection
- Palpation
- Percussion
- Ballottement
- Auscultation
- Combined Auscultation and Percussion
- Special Diagnostic Techniques (paracentesis, cerebrospinal fluid, examination of ruminal fluid)

*The Clinical Examination.* The actual clinical examination consists of a:

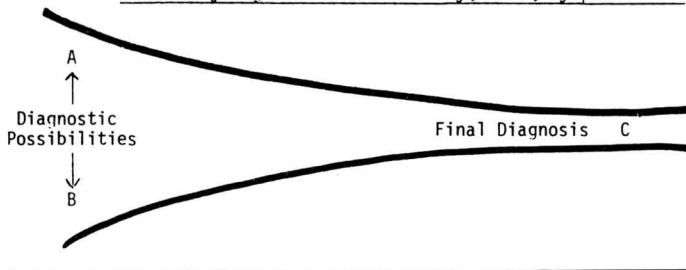
- A. General inspection of body regions
  - B. Close physical examination of each body system
- A. General Inspection (this is done from a distance by audiovisual inspection).
- a) Behaviour and general appearance
 

behaviour	posture
voice	gait
eating	bodily condition
defecation	conformation
urination	skin and hair coat

*b) Inspection of body regions*

- Head* (face, eyes, ears, nostrils)
- Neck* (jugular vein, brisket)
- Thorax: Respirations*
  - Rate*
  - Rhythm* (inspiratory, expiratory)
  - Depth* (shallow or deep)
  - Type* (abdominal or thoracic)
  - Noises* (coughing, sneezing, wheezing, snoring, grunting)
- Abdomen: Contour*
- Distended*
- Gaunt*
- Symmetry*
- External Genitalia*
- Mammary Gland*
- Limbs*

Figure 2. Schematic illustration of the large number of diagnoses which are possible when presented with an animal with a clinically significant abnormality, i.e., dyspnea



**B. The Close Physical Examination (all methods of examination are used)**

Begin the examination at the rear end of the cow. A urine sample is usually easily obtained by stroking the cow's vulva before other examinations are made. Next, the cow's rectal temperature should be taken. During the recording of the rectal temperature the vulvar mucous membranes may be examined for color and presence of discharges and/or lesions. The pulse rate is counted and the quality of pulse is assessed using the middle coccygeal artery of the tail at about the level of the tip of the vulva. The hair coat and skin may be assessed at this time for evidence of dehydration, loss of hair and skin lesions. The area over the tail head and the perineal region should be noted for any evidence of mange. The amount and nature of feces should be noted at this time and any abnormalities should be further investigated by obtaining more history.

**The animal is then examined on the left side in the following systematic manner.**

1. *Examination of the thorax* includes palpation, auscultation and percussion of the cardiac area (precordium) and the lung area.

*Cardiac area.* Palpation of the heart action has real value, the size of the cardiac impulses can be assessed and

palpable thrills may on occasion be of more value than auscultation of murmurs. It is best carried out with the palm of the hand and should be performed on both sides. An increased cardiac impulse, the movements of the heart against the chest wall during systole, may be easily seen on close inspection of the left precordium and can be felt on both sides. It may be due to cardiac hypertrophy or dilation associated with cardiac insufficiency or anemia or to distension of the pericardial sac with edema or inflammatory fluid. Care should be taken not to confuse a readily palpable cardiac impulse due to cardiac enlargement with one due to contraction of lung tissue and increased exposure of the heart to the chest wall. Normally the heart movements can be felt as distinct systolic and diastolic thumps. These thumps are replaced by thrills when valvular insufficiencies or stenoses or congenital defects are present. When the defects are large the murmur heard on auscultation may not be very loud, but the thrill is readily palpable. Early pericarditis may also produce a friction thrill. The cardiac impulse should be much stronger on the left than the right side and reversal of this situation indicates displacement of the heart to the right side. Caudal or anterior displacement can also occur.

In auscultation of the heart the points to be noted are the rate, rhythm, intensity and quality of sounds and whether abnormal sounds are present. Comparison of the heart and pulse rates will determine whether there is a pulse deficit due to weak heart contractions failing to cause palpable pulse waves: this is most likely to occur in irregular hearts. Normally the rhythm is in three time and can be described as LUBB-DUPP-pause, the first sound being dull, deep, long and loud and the second sound sharper and shorter. As the heart rate increases the cycle becomes shortened mainly at the expense of diastole and the rhythm assume a two-time quality. More than two sounds per cycle is classified as a "gallop" rhythm and may be due to reduplication of either the first or second sounds. Reduplication of the first sound is common in normal cattle. The rhythm between successive cycles should be regular except in the normal sinus arrhythmia associated with respiration. With irregularity there is usually variation in the time intervals between cycles and in the intensity of the sounds, louder sounds coming directly after prolonged pauses and softer than normal sounds after shortened intervals as in extrasystolic contractions. The intensity of the heart sounds may vary in two ways, absolutely or relatively: absolutely when the two sounds are louder than normal and relatively when one sound is increased compared to the other in the cycle. For example, there is increased absolute intensity in anemia and in cardiac hypertrophy. The intensity of the first sound depends on the force of ventricular contraction and is thus increased in ventricular hypertrophy and decreased in myocardial asthenia. The intensity of the second sound depends upon the semilunar closure, that is on the arterial blood pressure and is, therefore, increased when the blood pressure is high and decreased when the pressure is low.

Abnormal sounds may replace one or both of the normal sounds or may accompany them. The heart sounds are muffled when the pericardial sac is distended with fluid. Sounds which are related to events in the cardiac cycle are murmurs or bruits and are caused mainly by endocardial lesions such as valvular vegetation or adhesions, insufficiency of closure of valves and to abnormal orifices such as a patent interventricular septum or ductus arteriosus. Interference with normal blood flow causes the development of turbulence with resultant eddying and the creation of murmurs. In attempting to determine the site and type of lesion it is necessary to identify its time of occurrence in the cardiac cycle; it may be presystolic, systolic or diastolic and it is usually necessary to palpate the arterial pulse and auscultate the heart simultaneously to determine accurately the time of occurrence. The site of maximum audibility may indicate the probable site of the lesion, but other observations including abnormalities of the arterial pulse wave should be taken into account. In many cases of advanced debility, anemia and toxemia soft murmurs which wax and wane with respiration (hemic murmurs) can be heard and are probably due to myocardial asthemia. In cases of local pressure on the heart by other organs, for example in diaphragmatic hernia in cattle, loud systolic murmurs may be heard, due probably to distortion of the valvular orifices.

Abnormal sounds not related to the cardiac cycle include pericardial friction rubs which occur with each heart cycle but are not specifically related to either systolic or diastolic sounds. They are more superficial, more distinctly heard than murmurs and have a to-and-fro character. Local pleuritic friction rubs may be confused with pericardial sounds especially if respiratory and cardiac rates are equal.

*Lung area.* Palpation, percussion and auscultation are again the methods available for examination of the lung area. Palpation may reveal the presence of a pleuritic thrill, bulging of the intercostal spaces when fluid is present in the thoracic cavity, or narrowed intercostal spaces and decreased rib movement over areas of collapsed lung.

The lung area available for satisfactory auscultation is slightly larger than that available for percussion. The normal lung sound or vesicular murmur is heard over the bulk of lung tissue, particularly in the middle third anteriorly over the base of the lung and is a soft, sipping VEE-EFF, the latter, softer sound occurring at expiration. The sounds are caused by the movement of air in and out of alveoli and are heard with variable ease depending on the thickness of the chest wall and the amplitude of the respiratory excursion. In fat beef cattle the sounds may not be discernible at rest. Increased vesicular murmurs are heard in dyspnoea and in early pulmonary congestion and inflammation. The vesicular murmur may be diminished or absent when the alveoli and small bronchi are not filling with air, as in the later stages of pneumonia, pulmonary edema and collapse. Bronchial tones are the sounds produced by the passage of air through the larger air passages and in normal animals are audible only at the base of the lung. If the lung is collapsed

there is no exudate in the bronchi, such as occurs in interstitial pneumonia, the area over which bronchial tones may be heard is much increased.

Alterations in the vesicular murmur and bronchial tones are the most common abnormalities which are audible on auscultation of the lung area in animals with disease of the lower respiratory tract. Other abnormal sounds over the lung area include rhonchi, rales, friction rubs and loud crackling sounds. They are the result of interference with the free movement of air in and out of the lungs, and of the presence of lesions which interfere with the normal movement of the lung and thus create additional respiratory sounds which are an indication of disease. The narrowing of the lumen of the tracheobronchial tree will result in sounds which have a musical quality (rhonchi or dry rales). The presence of fluid or exudate in the lumen of the tracheobronchial tree will result in coarse, medium or fine rales or crepitant sounds due to movement of inspired or expired air through the fluid. The presence of air in the interstitial spaces, due to rupture of alveoli, will result in loud crackling sounds. The rubbing together of abnormal visceral and parietal pleural surfaces as in pleuritis or severe emphysema with over-inflation of the lung will result in a pleuritic friction rub.

There is considerable variation in the descriptions of the characteristics and the interpretations of the significance of abnormal lung sounds (Table 1).

The intensity of abnormal lung sounds may be increased and their clarity improved by measuring the rate and depth of respirations with forced mild exercise such as walking for a few minutes followed by immediate auscultation. If exercise is undesirable the occlusion of both nostrils for 30 to 45 seconds will be followed by some deep inspirations and accentuation of abnormal lungs. This can also be accomplished by placing a plastic bag over the animal's head for up to 2-3 minutes. This will result in hyperpnea and accentuation of abnormal lung sounds.

**Sounds of peristalsis are normally heard over the lung area on the left side. In cattle these sounds are due to reticular movement. In cattle, too, sounds of swallowing, belching and regurgitation may be confused with peristaltic sounds; ruminal movements and the esophagus should be observed for the passage of gas or a bolus to identify these sounds.**

Percussion may be the usual direct means, or indirectly by tracheal percussion when the trachea is tapped gently and the sound listened for over the lung area. By direct percussion within the intercostal spaces the area of normal lung resonance can be defined and abnormal dullness or resonance detected. Increased dullness may indicate the presence of a space-occupying mass, consolidated lung, edematous lung or an accumulation of fluid. An overloud normal percussion note is obtained over tissue containing more air than usual, for example emphysematous lung. A definite tympanitic note can be elicited over pneumothorax or a gas-filled viscus penetrating through a diaphragmatic



**Table 1. Identification and Clinical Significance of Respiratory Sounds**

<i>Lung Sound</i>	<i>Identifying Characteristics</i>	<i>Significance</i>
Increased vesicular sounds	Increased amplitude of vesicular sounds, audible with ease, heard on expiration and inspiration	Occurs in fever, after exercise, high environmental temperature, early pneumonia
Decreased vesicular sounds	Decreased amplitude of vesicular sounds, audible on early inspiration not on expiration, difficult to hear	Any disease resulting in decreased volume of alveolar space (pneumonia, pulmonary edema, and/or fluid accumulation in pleural cavity)
Increased bronchial tones	Increased amplitude of bronchial breath sounds, begin and end abruptly, on inspiration and expiration	Any disease resulting in collapse or filling of alveolar spaces and leaving bronchial lumen open. Suggests consolidation. Heard commonly in cattle with severe pneumonia and calves with enzootic pneumonia
Rhonchus (dry rales)	Continuous musical type humming, whistling, squeaking and wheezing, which occur primarily on expiration although they frequently are heard during both inspiration and expiration	Originate in the lumen of the tracheobronchial tree, resulting from narrowing, mucosal irregularities or thick tenacious exudate all of which produce turbulence and eddy formation. Sonorous rhonchi originate in the large bronchi and are low-pitched. Sibilant rhonchi originate in the smaller bronchi and are high-pitched. Sonorous rhonchi suggests chronic bronchitis, sibilant rhonchi are common in chronic exudative pneumonia with small amounts of tenacious exudate in the bronchioles

**Table 1 continued**

Lung sound	Identifying Characteristics	Significance
Expiratory grunting	Loud groaning and grunting on expiration which is usually forced and against a partially closed glottis with sudden release, audible on auscultation of the thorax, over the trachea and often audible without the aid of a stethoscope	Severe diffuse pulmonary emphysema, extensive consolidation, severe pleurisy, acute peritonitis
Coarse rales	Coarse, bubbling, moist sounds primarily on inspiration. Coarse rales are easily moved by coughing	Suggest the presence of movable exudate in the large bronchi and trachea. Heard in exudative pneumonia, exudative tracheo-bronchitis, aspiration pneumonia
Fine rales (crepitant or crackling rales)	Fine crackling sizzling sounds on inspiration	Suggest the presence of exudate in the terminal bronchioles. Also occur when collapsed bronchi are dilated by the passage of air as in early pneumonia and emphysema
Loud crackling breath sounds	Harsh crackling sound on inspiration and expiration	Suggests alveolar and interstitial emphysema. especially in cattle
Pleuritic friction rubs	'Sand Papery' rather than crackling. Dry, grating, sound close to the surface, on inspiration-expiration, tend to be jerky and not influenced by coughing	Pleuritis, diffuse pulmonary emphysema with a dry pleural surface. Diminish or disappear with pleural effusion
Peristaltic sounds	Intermittent gurgling sounds	Are normal, especially after eating. Do not indicate diaphragmatic hernia unless other signs are present

Table 1 continued

Lung sound	Identifying Characteristics	Significance
Absence of lung sounds (both vesicular and bronchial)	Loud sounds not audible with careful auscultation	Bronchial lumen filled with exudate, space-occupying mass, diaphragmatic hernia, pleural effusion
Laryngeal stertor	Loud stenotic sounds on inspiration audible with or without stethoscope over the trachea	Suggests obstruction of the larynx (due to edema, laryngitis, paralysis of vocal cord). Prime example is calf diphtheria

hernia. For percussion to be a satisfactory diagnostic aid affected areas need to be large with maximum abnormality, and the chest wall must be thin.

2. Palpate the left neck, jugular groove and left prescapular lymph node.
3. Examine the left paralumbar fossa and abdomen.

(a) **rumen**

*Visual inspection.* Can you see the rumen pack? Is the fossa distended due to ruminal tympany or a displaced abomasum?

*palpation.* Can you palpate the rumen pack?

*auscultation.* Listen for the ruminal movements for at least 3 minutes. Identify primary and secondary contraction of the rumen.

*Percussion and auscultation* to detect a ping associated with an atonic rumen or pneumoperitoneum.

(b) **Left-sided displacement of the abomasum**

*Auscultate for the spontaneous percolating and tinkling sounds* associated with a displaced abomasum.

*Auscultate and percuss between the 9th and 12th rib* for evidence of a high-pitched ping associated with a displaced abomasum.

*Auscultate over the paralumbar fossa and then over area where the abomasum is commonly displaced to detect the presence or absence of ruminal sounds.*

The stomach tube test may be useful to differentiate between an atonic rumen and a left-side displacement of the abomasum, in both of which there is a "ping" on percussion. The tube is passed into the rumen and an assistant blows on the tube while the examiner auscultates over the left

paralumbar fossa. The character and magnitude of the bubbling sounds are noted at the level of the fossa. The examiner then auscultates over the area where the ping, suspected to be due to the displaced abomasum, is loudest. If the abomasum is displaced, the bubbling sounds from the tube are much reduced in intensity. If the abomasum is not displaced, the intensity of the sounds at both sites is about the same.

4. **Palpate the left prefemoral lymph node before leaving the left side. Then examine the right side of the cow which includes the following:**

1. Examination of the thorax (already described for the left side).
2. Palpation of the right neck, jugular groove and right prescapular lymph node.
3. Examination of the right paralumbar fossa and abdomen:

Deep palpation and ballottement for distended viscera, gravid uterus and enlarged liver.

Auscultation and percussion for the presence of "pings" associated with the following:

- Cecal dilation and torsion
- Abomasal dilatation and torsion
- Intestinal tympany due to paralytic ileus or acute intestinal obstruction.
- Pneumoperitoneum following a laparotomy
- Presence of post-partum pings

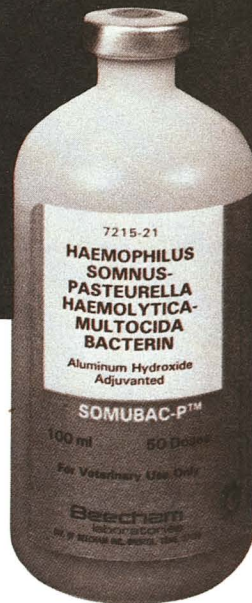
**Detection of Abdominal Pain**

Cattle with acute local or diffuse peritonitis may grunt with almost every expiration. The grunt is exaggerated in the recumbent position. However, grunting may also be caused by severe pneumonia, pleurisy and severe pulmonary emphysema. Careful auscultation and percussion of the



# Give new feeders superior protection against *Haemophilus somnus*.

Doctor,  
Your clients are reading this ad in  
Feedlot Management and Calf News.  
They'll be coming to you for Somubac-P.<sup>™</sup>  
Cordially,  
Gaston Cowell, Manager  
Veterinary Sales + Marketing  
Beecham Laboratories



## Somubac-P<sup>™</sup>

contains three different  
*H. somnus* strains for  
broader immunity.

You know how *H. somnus* could cripple your feeder operation. You also need to know what bacterin offers superior protection against it. Somubac-P is a combination product which gives greater immunity against three types of *H. somnus*, plus *Pasteurella haemolytica*, Type 1 and *Pasteurella multocida*, Type A.

To understand how Somubac-P provides

superior protection, consider the complexity of *Haemophilus somnus*. Scientists have identified three different strains, any one of which can cause the disease in varying forms.

Somubac-P contains all three of these killed *H. somnus* strains. Its superior protection has been demonstrated in carefully controlled tests in laboratory

animals\* Both the *H. somnus* portion and the combined portions of Somubac-P provided greater immunity against *H. somnus* than another commercial *H. somnus* bacterin.

When your new feeders arrive, give them Somubac-P for superior protection against *H. somnus*. Your veterinarian has it in stock or can get it for you.

\*Data on file at Beecham Laboratories and the U.S.D.A. The correlation between standardized mouse potency tests and clinical results in cattle has not been clearly established.

**Beecham**  
Biologicals

Making the world a safer place.

BEECHAM LABORATORIES, DIV. OF BEECHAM INC., BRISTOL, TN. 37620



QUALITY, The Mark Of A Licensed Vaccine

©1981, Beecham Lab., Div. of Beecham Inc.



lungs is therefore necessary to exclude the presence of pulmonary disease.

Not all *grunts* occur spontaneously. Deep palpation of the abdomen using the closed hand or knee is often necessary to elicit a grunt. Auscultation over the trachea is often necessary to hear the grunt. The grunt is best produced if pressure is applied to the abdomen at the end of inspiration and the beginning of expiration. The inspiratory and expiratory sounds are auscultated for 6 to 8 respirations and then without any particular warning the pressure is applied to the abdomen. The presence of a grunt means the presence of a peritoneal lesion (stretching, inflammation, edema). The absence of a grunt does not exclude the presence of a peritoneal lesion. In acute traumatic reticuloperitonitis the grunt may be absent in 3 to 5 days after the initial penetration of the reticulum.

A rigid bar or wooden pole may be necessary to apply pressure in large cattle (large cows and bulls). The bar is held by two people in a horizontal position just behind the xiphoid sternum while a third person auscultates over the trachea when the bar is lifted quickly up into the abdomen. Several attempts should be made to elicit a grunt before concluding the absence of a grunt. The ventral and both sides of the abdomen should be examined beginning at the level of the xiphoid sternum and moving caudally to a point caudal to the umbilicus. In this way the anterior and caudal aspects of the abdomen will be examined for evidence of painful points.

Pinching of the withers is also used to elicit a grunt. In the average sized cow, pinching of the withers causes the animal to depress its back. In an animal with an inflammatory lesion of the peritoneum, depression of its back will commonly result in a grunt which may be audible without auscultation over the trachea, but auscultation will usually be necessary.

#### **Rectal Examination**

A rectal examination is indicated when abnormalities of the abdomen are detected by physical examination of the abdomen or when the diagnosis is not obvious. The following observations should be made:

1. *The amount and nature of feces and the presence of blood in the rectum*
2. *The condition of the rectal wall.*
3. *The structures which are palpable in their normal state include the following:* the caudal sacs of the rumen, the left kidney, the deep inguinal lymph nodes, the uterus and the bladder. Under normal conditions the small and large intestines, the abomasum and omasum, and the liver cannot be palpated.

*The following are commonly palpable when abnormal:*

- A dilated and distended cecum
- Intestinal tympany - primary or secondary (distended loops of small or large intestine)
- Distended abomasum and/or omasum
- Intussusception
- An enlarged liver
- An enlarged kidney and ureters

- Fibrinous adhesions of the caudal abdomen
- Abnormalities of the reproductive tract, bony skeleton, lymph nodes and bladder

For purposes of recording, the presence of abnormalities palpable on rectal examination of the abdomen can be divided, as viewed from the rear of the cow, into 4 quadrants: upper and lower left and upper and lower right quadrants.

The examination of the genito-urinary system includes visual inspection of the vulvar mucous membranes and palpation of the vagina, cervix, uterus, bladder, ureters and kidneys through the vagina and by rectal palpation. *Examination of the oral cavity* includes visual inspection of the mucous membranes for the presence of lesions. It is important to be able to distinguish between erosions, vesicles, ulcers and proliferative lesions. By using a simple mouth gag or by exteriorizing the tongue and with a strong flashlight it is possible to examine all aspects of the oral cavity which includes the state of the tongue, the pharynx and the larynx. The larynx may be examined in detail by the use of a long, cylindrical plastic vaginal speculum and a strong flashlight.

*Examination of the eyes and eyesight include the following:*

1. The menace reflex or blink reflex is done by thrusting the partially flexed hand in front of the animal's eye and observing the closure of the eyelids. *This is an excellent test for the presence of blindness in cattle.*
2. The pupillary light reflex is conducted with a strong flashlight.
3. The state of the cornea, sclera, pupil and anterior chamber of the eye can be examined with a direct light source.
4. The fundus of the eyes should be examined with an ophthalmoscope. The common lesions of the fundus of the eyes of cattle include: optic disc edema in vitamin A deficiency, Polioencephalomalacia and lead poisoning and other diseases which cause increased intracranial pressure, and the hemorrhagic retinal lesions associated with *Hemophilus meningoenephalitis*.

*Examination of the musculoskeletal system includes the following:*

Is the animal able to walk and stand normally? Is the animal recumbent and unable to stand? The muscles, bones, joints, ligaments and tendons and feet are examined by visual inspection and palpation. Arthrocentesis of joints to obtain joint fluid for laboratory examination is indicated when the joints are enlarged.

*Examination of the nervous system* is a major subject which will not be presented here, but a detailed neurological examination, when necessary, includes examination of the following:

1. The gait
2. The cranial nerves
3. The spinal reflexes
4. Examination of the cerebrospinal fluid

*Examination of the mammary gland* includes physical palpation of the udder for presence of enlargement of the quarters, increased or decreased temperature and firmness. The skin of the teats, the teat cistern and the streak canal and teat end must also be examined. Milk samples are examined using a strip cut with a strip plate for any gross evidence of water milk, clots, purulent material or clumps of cells which are barely visible to the naked eye as may be seen in coliform mastitis. The California Mastitis Test is used for indirect examination of the total number of cells in the milk from each quarter. Suitable milk samples may be taken for culture of mastitis pathogens.

#### Simple Diagnostic Tests

Several simple diagnostic tests can be done in the field to supplement the physical examination of certain body systems:

1. *Paracentesis* (abdomen, thorax, pericardium and other swellings). This is very useful for the diagnosis of *peritonitis*, *pleuritis*, *pericarditis* and *cellulitis*.

2. *Rumen juice*. Examine the rumen juice for pH and protozoan activity.

3. *Urine*. Gross examination for the presence of red blood cells, turbid and cloudy material, or hemoglobin. Wide range pH paper or Labstix can be used for the determination of ketone, glucose, protein, and the presence of blood in urine. Cattle affected with right-sided distention of the abomasum may be in a state of paradoxical aciduria and the urine pH will be below 6.

4. *Cerebrospinal fluid*. Cerebrospinal fluid can be obtained with relative ease by puncture of the cisterno-medullary cavity. However, the cerebrospinal fluid must be examined within minutes after its collection. The fluid may be placed and dried on a glass slide and examined later for the presence of cells.

5. *California Mastitis Test* on milk.

6. *Hemetest* for occult blood in feces.

#### Interpretation of the Clinical Abnormalities and Making a Diagnosis

The clinical abnormalities found on clinical examination will suggest the body systems which are affected. These body systems must then be examined in detail to determine the *location of the lesion* in the system, the *type of lesion* and the *specific cause of the lesion*.

The *location of the lesion* is determined by clinical examination of the body system combined with special diagnostic procedures such as endoscopy, paracentesis, radiography and laparotomy. A detailed neurological examination is necessary to localize the lesion in a cow with paralysis of the hindlegs.

The abnormality observed may be produced by lesions of different *types*. In general, lesions can be divided into *anatomical or physical lesions* and *functional disturbances*. Physical lesions can be further subdivided into *inflammatory*, *degenerative* or *space-occupying*. These classifications are not mutually exclusive, a lesion may be

both inflammatory and space-occupying, abscesses in the spinal cord or lung are typical examples. In these circumstances it is necessary to modify the diagnosis and say that such and such a lesion is space-occupying and may or may not be inflammatory.

The differentiation between functional disturbances and physical lesions is often extremely difficult because the abnormalities produced may be identical. For example, in a case of hypomagnesemia in a cow there is no physical lesion, but differentiation from the encephalitis of furious rabies may be impossible. As a rule, functional disturbances are transient, often recurring or fluctuating and are readily reversible by treatment, whereas structural lesions cause changes which are relatively static or at least change only gradually and are affected only gradually by treatment. This is by no means a regular rule; the acute abdominal pain of intestinal obstruction usually fluctuates, but the lesion is a physical one whereas the paralysis of parturient paresis of cattle is static, but the disturbance is functional only.

Differentiation between inflammatory, degenerative and space-occupying lesions is usually simple. Space-occupying lesions produce signs characteristic of pressure on surrounding organs and can often be detected by physical means. Inflammatory lesions are characterized by heat, pain, swelling and a local or generalized leucocytosis and, in severe cases, a systemic toxemia. A total white blood cell count and a differential count is a *sensitive, non-specific*, but very useful test for the presence of an infection causing a systemic illness. A leucopenia and neutropenia with a degenerative left shift suggests a severe infection such as coliform mastitis, acute diffuse peritonitis, septic metritis, pleuritis, severe bacterial pneumonia and a bacteremia (*Hemophilus* speticemia). A neutrophilia and a regenerative shift suggest an active chronic infection such as pericarditis, peritoneal and pulmonary abscesses and other deep body system infections which may not be readily detectable. Degenerative lesions produce the same loss or abnormality of function as lesions of the other types, but are not usually accompanied by evidence of inflammation unless they are extensive. If the lesion is accessible, a biopsy or paracentesis should be considered as a means of determining its nature.

*The specific cause of the lesion*. If the system involved, the nature of the abnormality and the type of lesion can be satisfactorily determined, it then remains to decide on the *specific cause of the abnormality*. If, for example, it could be said that a particular case of paralysis in a calf was caused by a degenerative lesion of the musculature, only a few specific etiological agents would have to be considered to make a final diagnosis. In many, if not most, cases it is impossible to go beyond this stage without additional techniques of examination, particularly laboratory examination, and it is a general practice to make a diagnosis without this confirmatory evidence because of limitations of time or facilities.

**It is at this stage that a careful history-taking and examination of the environment show their real value. It is**

only by a detailed knowledge of specific disease entities, the conditions under which they occur, the epidemiology and the clinical characteristics of each disease than an informal judgement can be made with any degree of accuracy. If the diagnostic possibilities can be reduced to a small number, confirmation of the diagnosis by laboratory methods becomes so much easier because there are fewer examinations to be made and confirmation by response to treatment is easier to assess. If it is necessary to treat with a great many drugs serially, or in combination, to achieve a cure the expense is greater and the satisfaction of both the client and the veterinarian is diluted in proportion to the range of treatments. Accuracy in diagnosis means increased efficiency and this is the final criterion of veterinary practice.

An example of correlating the history and the epidemiological and clinical findings of a group of sick weaned beef calves 6 to 8 months of age, with the accepted knowledge of the diagnostic possibilities is presented here:

#### *History and Epidemiological Findings*

Recently weaned beef calves 6 to 8 months of age.

#### *Clinical Findings*

Dyspnea, mucopurulent nasal discharge, anorexia, toxemia, fever, abnormal lung sounds, low protective cough. *Differential Diagnosis* (in order of

probability)

Pneumonic pasteurellosis

Viral interstitial pneumonia

Infectious bovine rhinotracheitis

Atypical interstitial pneumonia

Pleuritis

Verminous pneumonia

For the *differential diagnosis*, make a list of the *possible diagnoses*, followed by a shorter list of the *probable diagnoses*, then the *tentative diagnosis* and finally the *final diagnosis*.


*What do you do if you cannot find significant abnormalities and cannot make a diagnosis?*

- Make a list of all the body systems and exclude those which are normal
- Re-examine the body systems which may be abnormal
- Do a hemogram to determine the presence or absence of a "hidden" infection
- Review the history carefully
- Come back and re-examine the animal several hours later if possible
- Consult with another veterinarian

**Diagnosis is the challenge and the opportunity.**

#### References

Fifth Edition (1979) Veterinary Medicine: — Blood, D.C. — Henderson, J.A. & O. M. Radostits: Lea & Febiger, Philadelphia.



*Dr. D. C. Blood, left & Dr. Otto Radostits*



# Scours... Easy come.

© Copyright American Association of Bovine Practitioners, open access distribution.

## Easy go.

Easy go with Vetisulid—backed by laboratory and field experiments which assure you of effective treatment against scours caused by *E. coli*, the most common infective organism.

Vetisulid is recommended for treatment of calf scours. It's available in 3 dosage forms— injection, oral boluses, and powder which can be mixed with milk or milk substitutes.

Withdrawal time—only 5 days after the last intravenous dose, 7 days after the last oral dose.

Check with your veterinarian to have the infection diagnosed right. Then ask about the benefits of going with Vetisulid.

## Vetisulid<sup>®</sup> Sulfachlorpyridazine

(pronounced 'Veta-sue-lid')  
available only from your  
veterinarian

