

A practical approach to neurologic disease in small ruminants

Meredyth Jones Cook, DVM, MS, DACVIM

Oklahoma State University, Stillwater, OK 74078
Large Animal Consulting & Education, Orlando, OK 73073

Key words: sheep, goat, neurologic disease

Veterinarians often shy away from a deep dive into cases with a neurologic component, often due to the complexity of the system and confusion around lesion localization. It is common to rely on treatments that are generically known to help with the most common or most treatable neurologic conditions and let the chips fall where they may. There is value, however, in having a working understanding of the characteristic clinical signs associated with each segment of the nervous system not only for the sake of the affected animal, but also for the benefit of the population in assessing risk. In this presentation, I will focus on the clinical signs associated with each segment of the nervous system to facilitate lesion localization and provide a list of differential diagnoses for diseases affecting each segment.

The Sign-Time Graph

Although not involved in lesion localization, the Sign-Time Graph is a useful tool that uses an accurate owner history for differentiating the umbrella etiologies of neurologic disease such as trauma, congenital, neoplastic or infectious. In the Sign-Time Graph, the x-axis represents the passage of time while the y-axis represents the severity of the clinical signs.

The Sign-Time Graph is represented in Figure 1. For example, clinical signs associated with trauma will peak early as there is damage and swelling of the tissue and then gradually the signs will decrease as the swelling subsides and the tissue heals. Contrast that with a neoplastic process where the clinical signs start mild and gradually increase in severity as the mass grows.

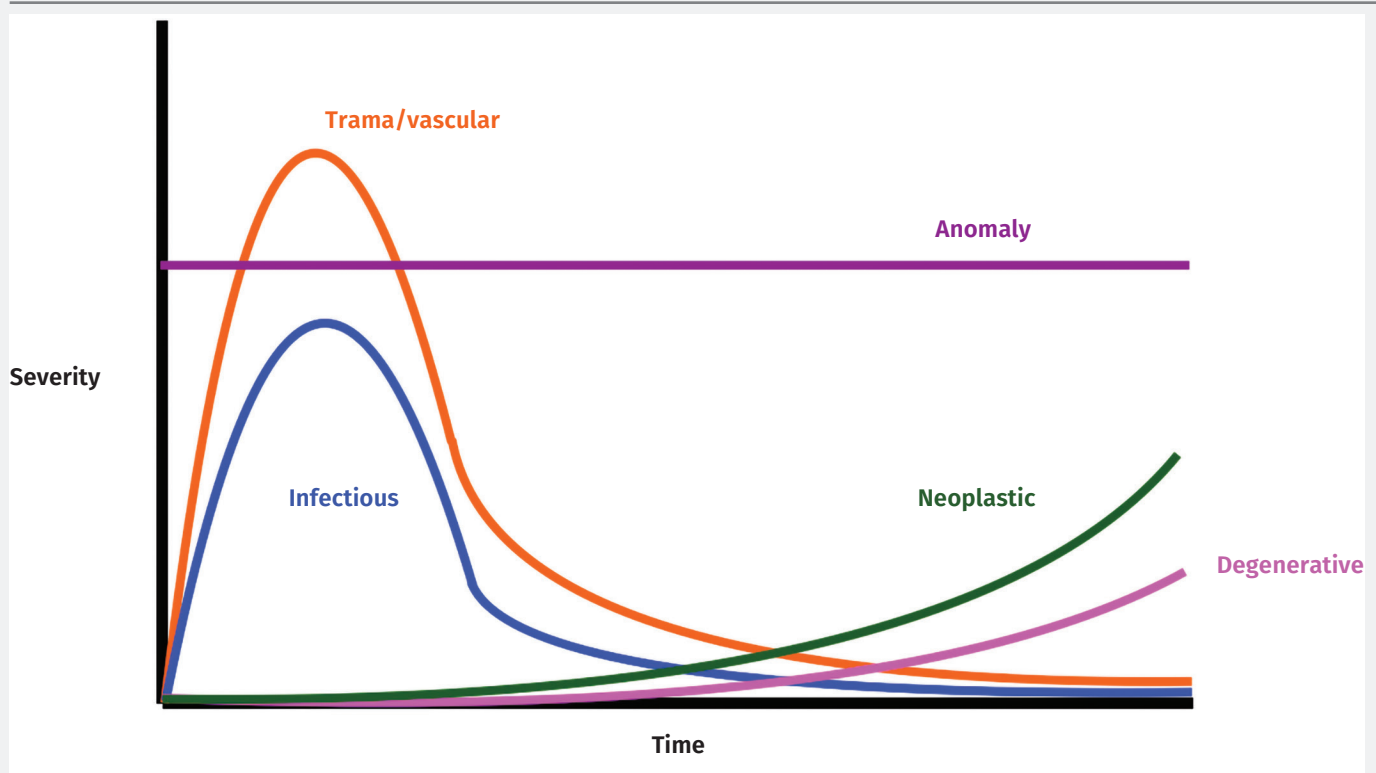
Cerebral diseases

Clinical signs associated with cerebral disease include a depressed or otherwise altered mental state, cortical blindness (blindness with an intact pupillary light response [PLR]), circling or leaning, head pressing, opisthotonus, vocalization, seizures and bizarre behavior.

The following list includes differential diagnoses for cerebral signs in small ruminants. Initially, age, signalment, environment, feeding and exposure history, and production status can be used to limit the list for an individual herd or patient:

- Polioencephalomalacia
 - ♦ Thiamine-responsive
 - ♦ Sulfur-induced
- Lead toxicity
- Vitamin A deficiency (blindness)

Figure 1: The Sign-Time Graph demonstrating the progression of clinical signs by diseases type over time.



- Salt toxicity/water deprivation
- Rabies
- *C. perfringens* C/D enterotoxemia
- Lidocaine toxicity
- Bacterial meningitis
- Scrapie
- CAE/OPP virus
- Urea Toxicity
- Hepatoencephalopathy
- West Nile Virus
- EHV-1, EEE others in camelids
- Thermal injury (disbudding)
- Hydrocephalus/Hydranencephaly
 - ◆ *Veratrum*, Bluetongue, Border disease, Cache Valley, Akabane (FAD)
- Heat Stress
- Listeriosis (can be an encephalitis in camelids)
- Sinusitis
- Cerebral Edema
- Hypoxia
- Hypoglycemia
- Acid-base derangement
- Uremia
- Hypocalcemia
- Grass Tetany
- Hypokalemia
- Brain Abscess
- Pituitary Abscess
- Pregnancy Toxemia
- Aberrant Parasite Migration
 - ◆ *P. tenuis*
 - ◆ *Neospora*
 - ◆ *Toxoplasma*
- Caprine Leukoencephalomyelitis
- Borna Disease
- Louping Ill (FAD)
- Dandy-Walker Malformation
- Holoprosencephaly
- Meningocele
- Anencephaly
- Neoplasia

Cerebellar diseases

Diseases of the cerebellum are fairly uncommon but are distinctive in their presentation and fairly easy to localize. With cerebellar lesions, animals will exhibit ataxia without paresis (wobbly but strong), intention tremors, nystagmus, truncal sway, a base-wide stance, hypermetria, picking up of the feet and slamming them down hard, falling over backwards and they may lack a menace response but have normal vision. They are generally mentally alert and have excellent muscle tone. In larger small ruminants, this combination of being ataxic but very strong can make them dangerous to handle.

Diseases with signs referable to the cerebellum include:

- Cerebellar Hypoplasia
 - ◆ Bluetongue virus, Border disease, Cache Valley virus, Rift Valley Fever, Wesselbron virus
- Cerebellar Abiotrophy
- Cerebellar Ataxia/Hereditary Hypomyelinogenesis
- Grass Staggers
 - ◆ Rye, Dallis, Bermuda, Canary Grasses
- Neoplasia
- Dandy-Walker Malformation

Brainstem diseases/central vestibular diseases

Clinical signs associated with the brainstem and the central vestibular system include depression, mania, ataxia with paresis, cranial nerve deficits, irregular respiration, heat tilt, eyelid droop, circling, hemiparesis, nystagmus, recumbency with lesion side down and with the contralateral limbs extended and hyper-reflexic and a loss of appetite.

Differential diagnoses associated with brainstem lesions include:

- Listeriosis
- Aberrant parasite migration (*Parelaphostrongylus tenuis*)
- Neoplasia

Peripheral vestibular diseases

Animals with peripheral vestibular diseases look very similar to animals with central vestibular disease with one main exception; animals with central disease are usually quite depressed while peripheral disease rarely results in depression. These animals can have a head tilt, ear droop, will lean, circle toward the lesion, have horizontal nystagmus, be ataxic without weakness, but be bright, alert and have a good appetite.

The peripheral vestibular diseases include:

- Bacterial otitis externa/media/interna
- Ear tick infestation
- *Psoroptes*, *Sarcoptes* mites

Spinal cord diseases

The spinal cord is one of the most common lesion sites seen in large animals, largely due to trauma. Lesions of the spinal are often mistaken for musculoskeletal disease as a cause of altered gait and may require extensive examination, palpation, gait observation and reflex testing to identify. Animals with spinal cord disease will present with ataxia with weakness (this is the main way to differentiate the ataxia of cerebellar diseases from ataxia of spinal disease), dysmetria and recumbency. These animals are mentally appropriate and are the typical “alert downer”. An altered mental state can occur in cases allowed to progress without good nursing care due to dehydration, acid-base or electrolyte/mineral deficiencies due to inability to access feed and water.

Causes of spinal cord lesions include:

- Trauma
- Pathologic fracture
- Vertebral body abscess
- Epidural abscess
- Aberrant parasite migration (*Parelaphostrongylus tenuis*)
- Neoplasia
- Ascending myelitis
- Botulism
- Tetanus
- Spastic paresis
- CAE/OPP virus
- Caprine leukoencephalomyelitis
- Polyradiculoneuritis
- Enzootic Ataxia/Swayback (copper deficiency)
- Grass staggers
- Tick paralysis
- Organophosphate toxicity
- Plant toxicity - *Conium*, *Lupinus*, *Nicotinia*
- Neoplasia
- Spina Bifida
- Arnold Chiari Malformation

Peripheral nerve diseases

Peripheral nerve diseases most often affect a single limb but in cases of complex trauma can affect multiple limbs. Clinical signs of peripheral nerve disease, regardless of limb, are decreased muscle tone, weakness, paralysis and rapid muscle atrophy. In general, disuse muscle atrophy occurs over weeks, while neurogenic muscle atrophy may occur over the course of days.

The following list provides the major peripheral nerves of the limbs and the postural changes associated with diminished function of that nerve:

- Obturator
 - ♦ Clinical signs: Cannot adduct hind limbs – splay hind legs
 - ♦ Cause: Dystocia, splits, pelvic fracture
- Sciatic
 - ♦ Clinical signs: Extended stifle, flexed hip, flexed or extended hock or fetlock
 - ♦ Causes: Trauma, inappropriate intramuscular injections, lumbosacral fracture, proximal acetabular fracture, femoral fracture
- Femoral
 - ♦ Clinical signs: Flexed stifle, extended hip, crouching stance
 - ♦ Causes: Trauma, extreme hindlimb extension, injection site reaction
- Peroneal
 - ♦ Clinical signs: Extended hock, flexed fetlock
 - ♦ Causes: Trauma, sciatic damage
- Tibial
 - ♦ Clinical signs: Partially knuckled fetlock, flexed hock
 - ♦ Causes: Trauma, sciatic damage
- Suprascapular
 - ♦ Clinical signs: Short-strided gait, abduction of the leg and shoulder during weight bearing, atrophy of supraspinatus and infraspinatus mm.
 - ♦ Causes: Trauma
- Radial
 - ♦ Clinical signs: Dropped elbow to complete forelimb paralysis
 - ♦ High damage: can't bear weight, flexed elbow and fetlock
 - ♦ Low damage: can bear weight, flexed fetlock
 - ♦ Causes: Trauma, rib or humeral fracture, avulsion of brachial plexus

Storage diseases

Finally, several storage diseases have been described in small ruminants. Although these conditions are rare, it is worth knowing they exist in certain breeds. Storage diseases are conditions in which proteins, enzymes or lipids are not appropriately metabolized as part of their metabolic pathway, causing accumulation and dysfunction. These conditions may affect one or multiple sites of the central nervous system and therefore the clinical signs may differ across cases. This list should not be considered exhaustive.

- β mannosidosis – Nubian, Nubian crosses
- GMI Gangliosidosis – Suffolk
- Generalized Glycogenolysis – Suffolk
- β galactosidase deficiency – Suffolk
- Globoid Cell Leukodystrophy (Krabbe's Disease) – Polled Dorset
- Galactocerebroside – Polled Dorset

Resources

Constable PD. Ruminant Neurologic Diseases, An issue of *Veterinary Clinics of North America: Food Animal Practice*. Elsevier Health Sciences; 2017 July.

<https://www.sciencedirect.com/journal/veterinary-clinics-of-north-america-food-animal-practice/vol/20/issue/2>

Articles:

- Clinical examination of the ruminant nervous system
- Diagnostic techniques and clinicopathologic findings in ruminants with neurologic disease
- Acquired spinal cord and peripheral nerve disease
- Brainstem and cranial nerve abnormalities: listeriosis, otitis media/interna, and pituitary abscess syndrome
- Cerebellar disease and disease characterized by dysmetria or tremors
- Altered mentation caused by polioencephalomalacia, hypernatremia and lead poisoning
- Transmissible spongiform encephalopathies in ruminants
- Viral disease of the ruminant nervous system
- Bacterial meningitis and encephalitis in ruminants
- Clostridial disease associated with neurologic signs: tetanus, botulism, and enterotoxemia
- *Parelaphostrongylus tenuis* and other parasitic diseases of the ruminant neurologic system
- Congenital defects of the ruminant nervous system

Washburn KE. Food Animal Neurology, An Issue of *Veterinary Clinics of North America: Food Animal Practice*. Elsevier Health Sciences; 2017 March.

<https://www.sciencedirect.com/journal/veterinary-clinics-of-north-america-food-animal-practice/vol/20/issue/2>

Articles:

- A practitioner's guide to diseases and conditions leading to neurologic dysfunction in the ruminant
- Neurologic examination of the ruminant
- Diagnostics and ancillary tests of neurologic dysfunction in the ruminant
- Localization of neurologic lesions in ruminants
- Cerebral disorders of calves
- Cerebral disorders of the adult ruminant
- Cerebellar disease of ruminants
- Brainstem and cranial nerve disorders of ruminants
- Spinal cord and peripheral nerve abnormalities of the ruminant
- Toxicoses of the ruminant nervous system

