

Using Teat Endoscopy (Theloscopy) to Diagnose and Treat Milk Flow Disorders in Cows

Thomas Geishauser, *Dr.med.vet.habil., FTA, MSc*¹

Klaus Querengässer, *Dr.med.vet.*²

¹ *Department of Population Medicine, Ontario Veterinary College, University of Guelph, Guelph, Ontario N1G 2W1, Canada, (corresponding author)*

² *Tierärztliche Klinik Babenhausen, Paradiesstraße 34, 87727 Babenhausen, Germany*

Abstract

Teat endoscopy (theloscopy) is an effective method to diagnose milk flow disorders, to visualize the cistern during surgery and to monitor response to treatment. The necessary equipment consists of a small wireless battery-operated theloscope for air insufflation and endoscopy, and appropriate sized surgical instruments. The patient should be sedated and properly restrained, including the tail and hindlimbs, prior to and during the procedure. Following cleaning and disinfection of the teat, an anesthetic should be injected into a teat vein. The affected teat should be drained, a clamp should be placed at the teat base, and the cistern flushed with sterile saline.

Theloscopy can be performed through either the lateral teat wall or the teat canal. When the approach is made through the teat wall, a small opening is made for endoscopic examination, which is sutured after the procedure has been completed. When endoscopic examination is performed through the teat canal, the teat canal and the teat cistern can be inspected through the theloscope in an upward direction. When the approach is through the lateral teat wall, both the teat cistern and the inner opening of the teat canal can be easily visualized; the view is directed in a downward direction. Theloscopy has been used in rural practice on several hundred patients. It can be a useful tool to diagnose and treat milk flow disorders.

Résumé

L'endoscopie des trayons (théloscopie) est une méthode efficace pour le diagnostic des problèmes d'écoulement du lait, pour la visualisation du réservoir durant la chirurgie et pour suivre la réaction suite au traitement. L'appareillage nécessaire comprend un

théloscope sans fil à batterie pour la soufflerie d'air et l'endoscopie et des instruments de chirurgie de taille appropriée. Le patient doit être sous sédation et bien retenu avant et durant la procédure aussi bien au niveau de la queue que des membres arrières. Suite au nettoyage et à la désinfection du trayon, un produit d'anesthésie devrait être injecté dans une veine du trayon. Le trayon à problème devrait être vidé de son lait, la base du trayon attachée et la citerne irriguée avec une solution saline stérile.

La théloscopie peut être conduite au niveau de la paroi latérale du trayon ou par le canal du trayon. Avec l'approche passant par la paroi du trayon, la petite incision faite pour l'examen endoscopique doit être suturée après la fin de la procédure. Lorsque l'examen endoscopique passe par le canal, le canal du trayon et sa citerne peuvent être inspectés avec le théloscope pointant vers le haut. Lorsque l'approche passe par la paroi du trayon, la citerne du trayon et l'ouverture interne du canal sont facilement discernés et la vue se fait vers le bas. La théloscopie a été utilisée en pratique rurale sur plusieurs centaines de patients et peut être un outil pratique pour diagnostiquer et traiter les problèmes d'écoulement du lait.

Introduction

Historically it has been difficult to accurately diagnose the cause of milk flow disorders in teats of cows. Inspecting, palpating, blind probing and hand milking the affected teat were helpful, but often sonography,^{4,31,38,39,45} radiography^{18,46,48} or thelotomy^{1,10,30,46,47} was necessary to make a definitive diagnosis. Teat endoscopy (theloscopy) offers a modern technique to more accurately diagnose milk flow disorders.

Theloscopy was first described by Wilhelm and Schebitz⁴⁴ in 1979, and later by Tulleners and Hamir⁴¹ in

1990. However, it was Medl and colleagues who introduced theloscopy to bovine practice.^{20-23,25} Since then numerous reports have been published on this subject.^{2,3,5-8,12-17,24,25-27,32-3}

The objective of this paper is to describe endoscopic examination (theloscopy) of the bovine teat.

General Considerations

Theloscopy is a method to more accurately diagnose and treat milk flow disorders. Two approaches have been successfully used; through the teat canal or through the lateral teat wall. When the approach is made through the teat canal (axial theloscopy), the view is directed upwards into the teat canal (Figure 1 and 2) or the teat cistern (Figure 3 and 4). When the approach is through the lateral teat wall (lateral theloscopy), the view is directed downwards into the teat cistern and onto the inner opening of the teat canal (Fürstenberg rosette) (Figure 5 and 6). In our experience, the most frequent disorders of the teat are located in the area of the inner opening of the teat canal, which are best visualized using the approach through the lateral teat wall.

Equipment Necessary for Theloscopy

The basic piece of equipment is a small, wireless, battery-operated theloscope used to inflate and examine the teat. Our preferred theloscope^a consists of a rigid scope, a blow pipe and a handle (Figure 7). The design of the scope allows for straight insight (0°) into the teat, and has a working length of 10 cm (3.9 in). The scope runs in a blow pipe which has an outer diameter of 3.0 mm. Air is blown through the blow pipe into the teat cistern to dilate the teat for examination. The scope and blow pipe are attached to the handle. The handle contains a lamp, an air pump and two batteries^b (or rechargables) which will power the lamp and the pump for several hours. The lamp and pump may be operated separately.

The instruments and equipment necessary for surgery include: thelometer to measure teat canal length^c; round-ended probe; milking tubes^{d,e}; California Mastitis Test (CMT); stretching forceps and rubber rings; obturator^f; slide tube^g; syringes; needles; teat knife^h; teat punch (thelotome)ⁱ; foreign body forceps^j; natural teat inserts^k; silicone implants^l; needle holder; dissecting forceps; scissors; needle-thread combination; swabs; and bandage^m. In addition, xylazine, oxytocin, 70% isopropyl alcohol, 0.9% saline solution and 2% lidocaine solution are needed.

Preparation of the Cow

Following evaluation of the case history and a brief physical examination, the cow is prepared for examination of the affected teat while she is in the standing position.⁹ The cow can be restrained in a claw trimming device. This device can be lifted up with a lifting tableⁿ or it can be left on the ground and the cow examined from a pit (Figure 8). Another option is to put the cow on a tilt table^o. Prior to examination of the teat, the cow is sedated with xylazine (0.2 ml of a 2% solution per 100 kg [220 lb] body weight IV) and administered oxytocin (30 IU IV). It is important to properly restrain the head, tail, and the leg of the cow that is next to the examiner (Figure 9). The teats should be thoroughly cleaned with warm water and soap, dried, degreased with 70% isopropyl alcohol, and a suitable surgical disinfectant applied. Strict aseptic technique is essential to minimize contamination and mastitis.

Preliminary Examination of the Teat

The external surface of the teat should be examined first. The teat canal, teat cistern and teat wall should be carefully palpated.⁹ Patency of the teat canal is determined by expressing a few streams of milk from the teat. Teat canal length can be determined with

^aTHELOSCOPE – teat endoscope, The Butler Company, Dublin OH

^bEnergizer LR 14, 1.5 V, 8000 mAh, www.energizer.com. There is also a 110 V power supply available for the THELOSCOPE

^cTHELOMETER – probe for measuring teat canal length, The Butler Company, Dublin OH

^dSTERIL – disposable milking tube, The Butler Company, Dublin OH

^eTHELOKAL – wide milking tube, The Butler Company, Dublin OH

^fObturator, The Butler Company, Dublin OH

^gSlide pipe, The Butler Company, Dublin OH

^hHUG's teat lancet, The Butler Company, Dublin OH

ⁱTHELOTOM – teat punch, The Butler Company, Dublin OH

^jTHELAB – teat foreign body forceps, The Butler Company, Dublin OH

^kNIT[®] – natural teat insert, The Butler Company, Dublin, OH

^lSIMPL[®] – silicone implant, The Butler Company, Dublin, OH

^mELLA – adhesive teat bandaging strips, The Butler Company, Dublin, OH

ⁿLifting table. Gruse, Aerzen/Germany, www.gruse.de

^oMobile tilt table for cattle, Bartmann, Lübbecke/Germany

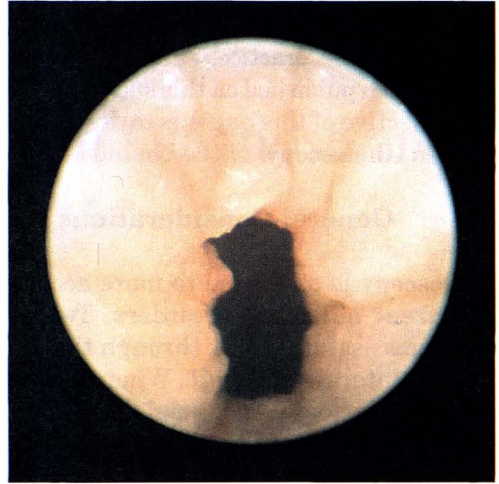


Figure 1. (left) View into the teat canal. Schematic representation. **Figure 2.** (right) Teat canal seen through the teat canal. Note longitudinal bulges thrown up by the underlying longitudinal muscle bundles.

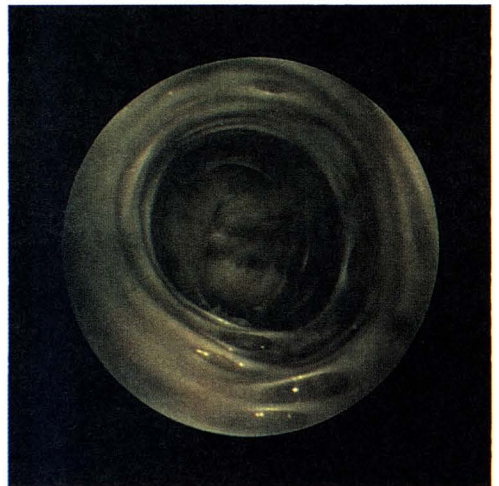


Figure 3. (left) View into the teat cistern. Schematic representation. **Figure 4.** (right) Teat cistern seen through the teat canal. Note circular folds and longitudinal blood vessels.

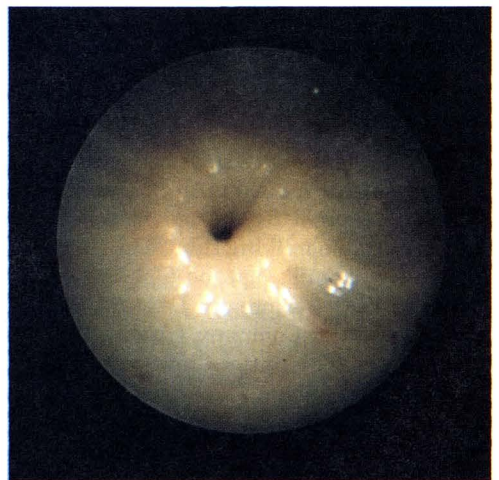
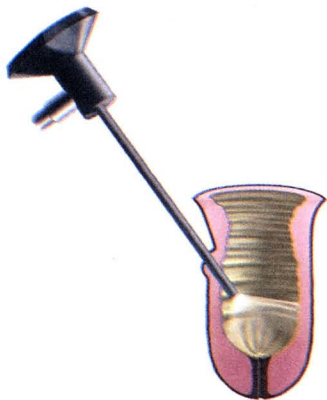


Figure 5. (left) View through the lateral teat wall. Schematic representation. **Figure 6.** (right) Inner opening of the teat canal (Fürstenberg rosette) seen through the lateral teat wall. Note radial folds.

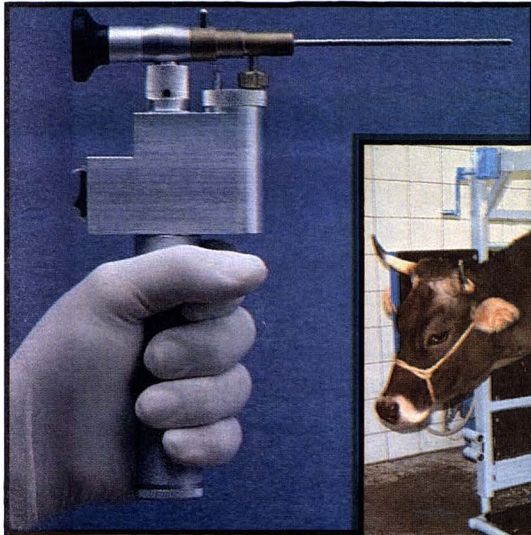


Figure 7.
THELOSCOPE –
wireless teat endoscope.




Figure 8. Teat examination may be performed with the cow in a claw trimming device and the examiner standing in a pit (teat surgery room of the Veterinary Clinic Babenhausen, Bavaria. Examiner Dr. Klaus Querengässer).

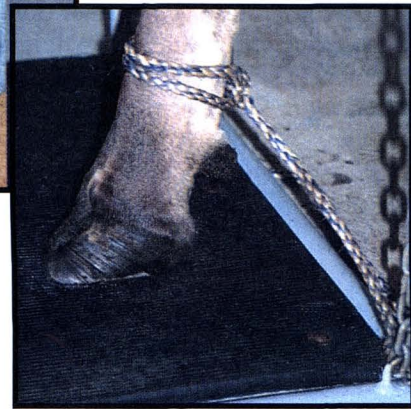


Figure 9. Fixation of the hind-limb that is next to the examiner.

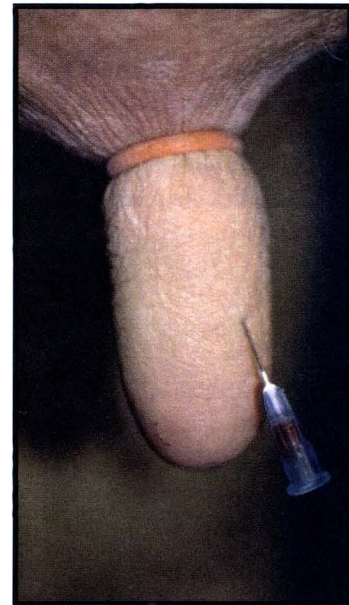
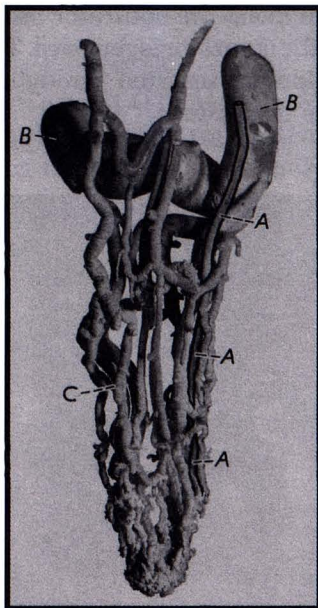


Figure 10. (left) Blood vessels in the teat: artery (A), part of the Fürstenberg vein ring (B) and veins (C). Plastiod.²⁹
Figure 11. (right) The teat is anesthetized by puncturing a teat vein with a 0.6 mm needle, draining blood and injecting 5 to 10 ml of a 2% lidocaine solution.

a thelometer, and the length compared to the contralateral teat. An increase in teat canal length of more than 2 mm is suggestive of a rupture in the teat canal area with inversion of tissue into the teat cistern.⁶ The course of the teat canal can be examined with a round-ended probe. A sterile milking tube may be used to test the patency of the teat canal and to obtain a milk sample. The CMT should be performed on each milk sample. Culture of milk and antimicrobial sensitivity testing are advisable if the CMT results suggest that the quarter is infected.

Preparation of the Teat for Theloscopy

Following initial examination of the teat canal, a rubber ring is placed around the base of the teat to prevent milk from entering the teat cistern, and to reduce blood flow to the teat wall. The teat is anesthetized by injecting 5 to 10 ml of 2% lidocaine solution into a teat vein (Figure 10 and 11).⁴⁰ The teat cistern is then rinsed with sterile saline through a milking tube until the draining saline is clear.

Axial Theloscopy

For axial thelосopy, the scope and blow pipe are inserted into the teat cistern through the teat canal. After activating the pump, air is blown into the teat to dilate the cistern, and with the lamp illuminated, the teat cistern is examined (Figure 12). The teat canal may be examined as the scope and blow pipe are removed.

Lateral Thelосopy

For lateral thelосopy, a small opening is made in the lateral teat wall by passing an obturator through the teat canal into the teat cistern, and pushing it through the lateral teat wall (Figure 13). Then the slide pipe is inserted along the obturator into the teat cistern (Figure 14), and the obturator is removed. The scope and blow pipe are then inserted through the slide pipe into the teat cistern. The slide pipe protects the edges of the opening during the examination. The air pump is switched on to dilate the cistern, and the lamp will illuminate the distal part of the teat cistern and the inner opening of the teat canal for inspection (Figure 15). To make ruptures in the area of the teat canal more visible, a milking tube can be placed into the teat canal while viewing the inner opening of the teat canal through the scope.

Treatment of Specific Conditions

Thelосopy is used for both diagnosis and surgical treatment.^{23,25} For treatment of most teat disorders, the

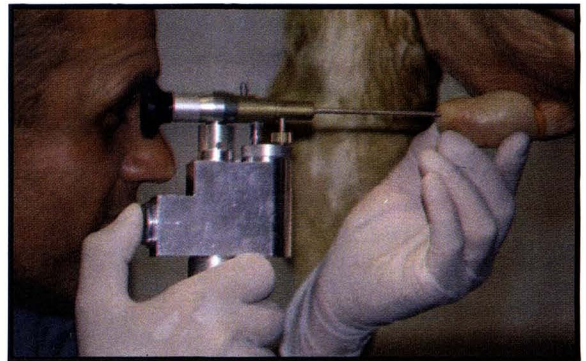


Figure 12. Thelосopy through the teat canal.

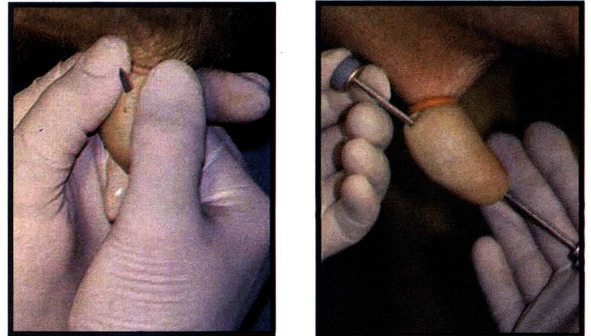


Figure 13. (left) For lateral thelосopy a small opening is made in the lateral teat wall. For this purpose an obturator is run through the teat canal into the teat cistern and pushed through the lateral teat wall.

Figure 14. (right) The slide pipe is inserted from outside along the obturator into the teat cistern and the obturator is removed. Then scope and blow pipe are inserted through the slide pipe into the teat cistern.

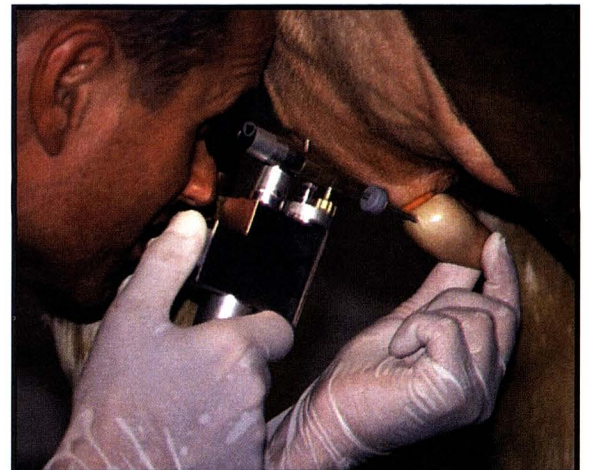


Figure 15. Thelосopy through the lateral teat wall.

thelotome (Figure 16) or Hug's lancet are used. Tissue impeding milk flow can be removed with the thelotome. A general guideline is "remove sick tissue – preserve healthy tissue". Tissue removal can be visualized through the theloscope inserted through the lateral teat wall (Figure 17 and 18). An assistant can hold the theloscope while the surgeon performs the treatment.

Incisions into the teat canal can be made with Hug's lancet to widen a strictured or narrowed teat canal. A general guideline is "one, two (at 0 and 180°) or three (at 0, 120 and 240°) V-shaped incisions in the area of the inner opening of the teat canal while attempting to preserve the outer teat canal opening" (Figure 19, 20 and 21). The incisions can also be made blindly without visualizing the procedure through the theloscope. For-

ceps can be used to remove bodies from the teat cistern that may originate from either inside (papilloma, blood or milk clots) or outside (foreign bodies) the teat (Figure 21 and 22).

Aftercare

The opening in the teat can be closed with a diagonal suture. The rubber ring applied at the teat base is best removed with scissors. Milk flow can be tested by hand-milking the teat. Residual milk should be drained from the quarter; normal milk can be drained with a narrow disposable milking tube (Figure 23), while mastitis milk often must be drained with a specially designed wide milking tube (Figure 24). Drain-

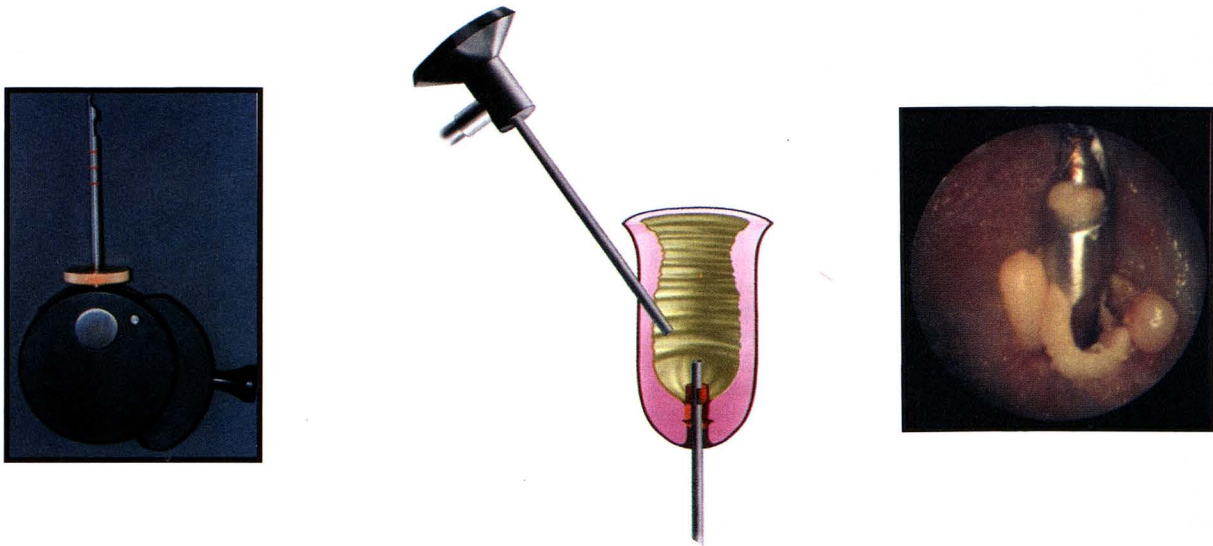


Figure 16. (left) THELOTOM – teat punch. **Figure 17.** (center) Visualizing the Thelotome treatment. Schematic representation. **Figure 18.** (right) Removal of tissue that had ruptured in the teat canal and inverted into the teat cistern by using the thelotome. Seen through the theloscope inserted through the lateral teat wall.

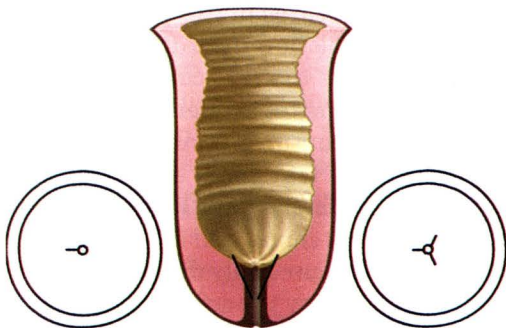


Figure 19. Making one, two or three V-shaped incisions in the area of the inner opening of the teat canal to widen the narrowed canal. Schematic representation.

Figure 20. Making an incision with Hug's lancet. Seen through the theloscope inserted through the lateral teat wall.

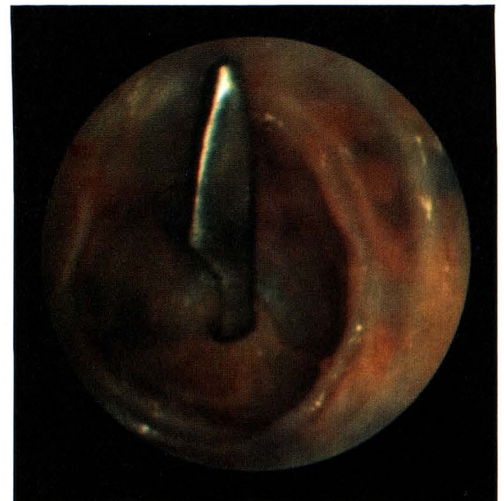



Figure 21. (left) THELAB – teat foreign body forceps.

Figure 22. (right) Removal of tissue that had plugged the inner opening of the teat canal by using a forceps inserted through the teat canal. Seen through the theloscope inserted through the lateral teat wall.

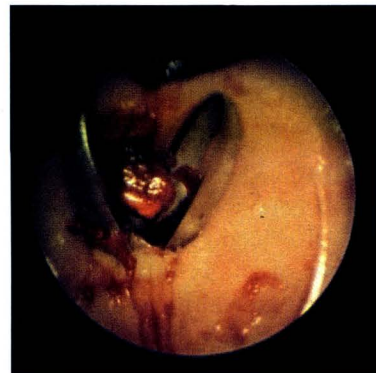
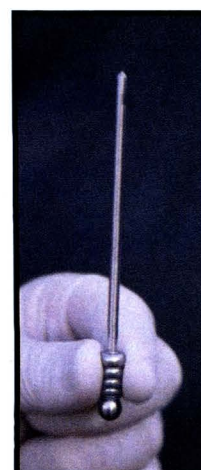


Figure 23. (left) Sterile disposable milking tube with Luer cone for draining normal milk. **Figure 24.** (right) THELOKAL – extra wide milking tube for draining mastitis milk.



ing the milk flushes residual tissue from surgery. An intramammary antibiotic should be infused into the teat cistern to prevent or to treat mastitis. Selection of the product should be based on the results of milk culture and sensitivity testing.⁴² A sterile silicone implant (Figure 25) or a sterile natural teat insert (Figure 26) is inserted into the teat canal to prevent teat canal stenosis. The suture is then removed, and the teat is bandaged by applying a strip of elastic long-lasting adhesive tape in a longitudinal manner (U-shape), (Figure 27) and applying another strip in a circular manner around the teat.

Teats are often rested for nine days after surgical intervention before routine milking is resumed.^{10,19,29,42,43} Often referred to as the 3x3-day method, milk is drained from the teat, a new teat insert is placed into the teat canal, and the teat is rebandaged on days 1, 4 and 7 postoperatively. A silicone implant is recommended during the first 3-day resting period and a natural teat insert during the second and third 3-day resting period. Beginning on day 10, the teat should be milked normally. If mastitis is present, the teat cannot be rested as the milk needs to be drained twice daily.

Conclusions

The procedure described in this paper was developed as a result of treating hundreds of cases in rural bovine practice. By using theloscopy instead of blind techniques, milk flow disorders can be precisely diagnosed. Recent studies have shown that the reason for the milk flow disorder in teats with undamaged skin can be visualized by theloscopy in 99% of the cases. In 48% of the cases, simple ruptures in the teat canal were diagnosed as reasons for milk flow disorders. In another 47%, ruptures in the area of the teat canal with inversion of teat canal skin into the teat cistern (acting like a valve) were found. In 1% ruptures occurred in the teat canal area with eversion of teat canal skin. 2% of the cases were caused by teat cistern papillomas occluding the inner opening of the teat canal, and 1% by ruptures in the teat cistern area. After precisely diagnosing these conditions the treatment is easy to perform. Another advantage of theloscopy over blind techniques is that treatment can be visualized and hence performed precisely. Our success rate has increased tremendously since we use theloscopy. In a recent study, cows whose milk flow




Figure 25. (left) A sterile SIMPL® silicone teat canal implant (yellow – thin, purple – thick) is inserted into the teat canal to prevent teat canal stenosis during first 3 day test resting period after surgery. **Figure 26.** (right) A NIT® natural teat insert keeps the teat canal patent during the second and third 3 day resting period. NIT's adjust to the teat canal and contain no medicaments. They disintegrate within a few days (The Butler Company, Dublin, OH).

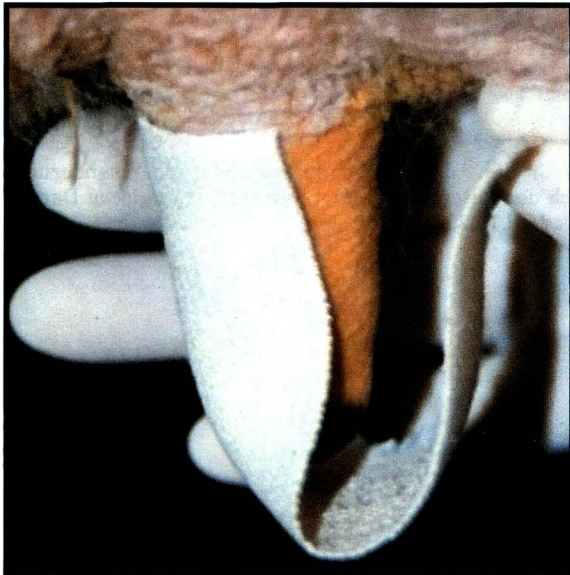


Figure 27. Bandaging the teat by using elastic long-lasting teat adhesive tape. One strip is applied longitudinally (U – shaped) and one strip is applied circularly. The bandage protects the teat, prevents the NIT® or SIMPL® from falling out, and indicates to the milker that the teat should not be milked.

disorders had been diagnosed and treated by using theloscopy yielded as much milk and stayed as long in the herd as herdmates.⁸ This has vastly improved from the past, when using blind treatment techniques often worsened the condition: cows often got mastitis after treatment and were culled.

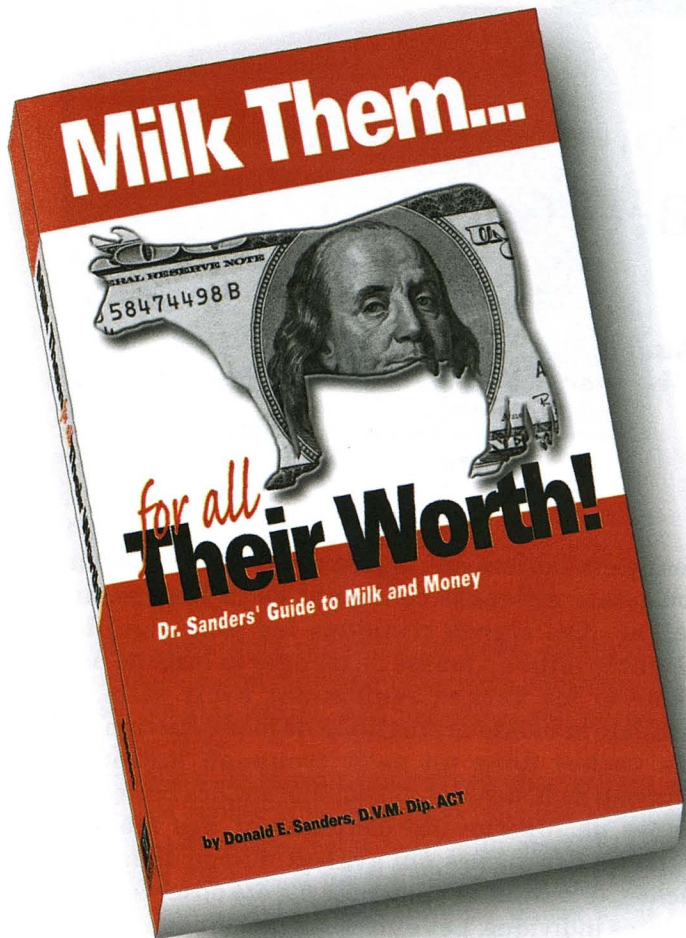
Acknowledgements

We thank Dr. Wolfgang Traeder and Georg Wolter from Pfizer in Karlsruhe, Germany for their assistance with making the schematic representations.

References

- Berchtold M, Rüscher P: Gedeckte Zitzenverletzungen. *VET 1*, No 9:12-15, 1986.
- Bleul U, Seeh C, Bostedt, H: Die endoskopiegestützte Therapie einer gedeckten Zitzenverletzung unter Verwendung eines neuartigen Strichkanalstabes beim Rind – ein Fallbericht. *Wien Tierärztl Wschr* 86:242-246, 1999.
- Bleul U, Seeh C, Teifke P *et al*: Resultate endoskopischer, sonographischer und histologischer Untersuchungen an der Zitzenzisternenschleimhaut des Rindes nach Behandlung mit Wollzitzenstiften. *Prakt Tierarzt* 81:590-601, 2000.
- Cartee RE, Ibrahim AK, McLeary D: B-mode ultrasonography of the bovine udder and teat. *J Am Vet Med Assoc* 188:1284-1287, 1986.
- Dümmer N: Vergleichende palpatorische, sonographische und endoskopische Untersuchungen der Zitzen eutergesunder und euterkranker Tiere. Hannover, Tierärztliche Hochschule, Dissertationsschrift, 1998.
- Geishauser T, Querengässer K: An evaluation of teat canal length in teats with milk flow disturbances. *J Dairy Sci* 83:1976-1980, 2000.
- Geishauser T, Querengässer K, Medl M: Neues zu gedeckten Zitzenkanalverletzungen bei Milchkühen? *Tierärztl Umsch* 53:480-487, 1998.
- Geishauser T, Querengässer, Nitschke M *et al*: Milk yield, somatic cell counts and risk of removal from the herd for dairy cows after developecovered teat canal injury. *J Dairy Sci* 82:1482-1488, 1999.
- Grunert E: Udder. in: Rosenberger G (ed): *Clinical examination of cattle*. Verlag Parey, Berlin and Hamburg, ed 2, 1979.
- Heidrich HJ: Ist bei Zitzenverletzungen laktierender Euterviertel ein zeitlich begrenztes Unterlassen des Milchentzuges vertretbar? *Prakt Tierarzt* 4:101-104, 1958.
- Heidrich, HJ: Therapie. in: Heidrich HJ, Renk W: *Krankheiten der Milchdrüse bei Haustieren*. Verlag Parey, Berlin and Hamburg, 464.
- Hirsbrunner G, Steiner A: Use of a thelosopic triangulation technique for endoscopic treatment of teat obstruction in cows. *J Am Vet Med Assoc* 214:1668-1671, 1999.
- Höptner C: Documentazione sugli effetti collaterali nell'applicazione di stiloidi e cateteri mammari nella bovina. Milano, Università, Tesi di Laurea, 1994.
- Hospes R, Seeh C: Untersuchungen zu den Operationsergebnissen nach theloresektoskopischen Eingriffen an der Zitze des Rindes. *Tierärztl Umsch* 53:420-429, 1998.
- Inzumisawa Y, Kobayashi T, Nagahata A, *et al*: Endoscopic appearance of the papillary duct and lactiferous sinus in cows (Japanese). *J Jap Vet Med Assoc* 48:175-179, 1995.
- John H, Hässig M, Gobet D, *et al*: A new operative method to treat high teat stenoses in dairy cows. *Br J Urol* 82:906-907, 1998.
- John H, Sicher D, Berger Pusterla D, *et al*: Videoassistierte theloskopische Elektroinzision einer hohen Zitzenstenose. *Schweiz Arch Tierheilk* 140:282-286, 1998.
- Kubicek J: Die röntgenologische Darstellung der Zitze des Rindes. *Tierärztl Umsch* 3:119-124, 1972.
- Kubicek J: Die gedeckten Zitzenverletzungen beim Rind. *Tierärztl Umsch* 30:59-65, 1975.
- Medl M, Querengässer K: Die Endoskopie der Zitze des Rindes. *Veterinär Spiegel* 3, No 3:4-11, 1994.
- Medl M, Querengässer K: Neue Behandlungen gegen Schwermelkbarkeit. *Top Agrar* 12/96:R16-R19, 1996.
- Medl M, Querengässer K: Erste Hilfe bei Zitzenverletzungen. *Top Agrar* 12/96:R20-R21, 1996.

23. Medl M, Querengässer K, Wagner C, et al: Zur Abklärung und Behandlung von Zitzenstenosen mittels Endoskopie. *Tierärztl Prax* 22:532-537, 1994.
24. Melle T: Vergleichende Studie zu diagnostischen Möglichkeiten bei tiefen Zitzenstenosen mittels Ultraschall und Endoskopie. Gießen, Justus-Liebig-Universität, FB 18, Dissertationsschrift, 1998.
25. Querengässer K: Diagnose und Therapie von Zitzenstenosen beim Rind mittels Endoskopie. Zürich, Universität, Veterinär-Medizinische Fakultät, Dissertationsschrift, 1998.
26. Querengässer K, Geishauser T, Höptner C: Effects of teat dilators and teat cannulas on udder health. *Bov Pract* 33.2:130-135, 1999.
27. Querengässer K, Geishauser T, Querengässer J, et al: Teat dilators as free foreign bodies in the bovine teat. *Bov Pract* 34.1:41-45, 2000.
28. Roux JMW le, Wilkens H: Beitrag zur Gefäßversorgung des Euters der Kuh. *Dtsch Tierärztl Wschr* 66:429-435, 1959.
29. Rüschi P: Die gedeckten Zitzenverletzungen beim Rind. Zürich, Universität, Veterinärmedizinische Fakultät, Habilitationsschrift, 1988.
30. Rüschi P, Berchtold M, Burkhardt H, et al: Auswirkungen des partiellen Trockenstellens eines Euterviertels bei Kühen mit Zitzenverletzungen. *Dtsch Tierärztl Wschr* 97:385-386, 1990.
31. Saratsis P, Grunert E: Ultraschalluntersuchung zur Abgrenzung der räumlichen Ausdehnung von Zitzenstenosen und anderen Zitzenveränderungen beim Rind. *Dtsch Tierärztl Wschr* 100:159-163, 1993.
32. Seeh C, Hospes R: Zitzenendoskopie. *Milchpraxis* 35:64-66, 1997.
33. Seeh C, Hospes R: Erfahrungen mit einem Theloresektoskop im Vergleich zur konventionellen Zitzenendoskopie bei der Diagnose und Therapie gedeckter Zitzenverletzungen. *Tierärztl Prax* 26:G110-G118, 1998.
34. Seeh C, Hospes R, Bostedt H.: Einsatz bildgebender Verfahren zur Diagnose der Beizitze beim Rind. *Tierärztl Prax* 24:438-442, 1995.
35. Seeh C, Melle T, Medl M, et al: Systematische Einteilung der Milchabflußstörungen des Rindes anhand endoskopischer Befunde unter besonderer Berücksichtigung der gedeckten Zitzenverletzungen. *Tierärztl Prax* 26:G174-G186, 1998.
36. Seeh C, Schlenstedt R, Stengel T, et al: Prüfung eines neuartigen Strichkanalstabes zur Behandlung von Strichkanalwunden unter besonderer Berücksichtigung der endoskopisch dokumentierten Schleimhautverträglichkeit im Vergleich zu konventionellen Zitzenstiften und Verweilkanülen. *Dtsch Tierärztl Wschr* 104:277-284, 1997.
37. Shakespeare AS: Use of endoscopy to investigate abnormalities within the bovine udder and teat. *Vet Rec* 142:672-673, 1998.
38. Stocker H, Rüschi P: Euter und Zitzen. in Braun U (ed): *Atlas und Lehrbuch der Ultraschalldiagnostik beim Rind*. Verlag Parey, Berlin, 163-175, 1997.
39. Stocker H, Bättig U, Duss M, et al: Die Abklärung von Zitzenstenosen beim Rind mittels Ultraschall. *Tierärztl Prax* 17:251-256, 1989.
40. Surborg H: Regionale intravenöse Anästhesie in der Zitzenchirurgie des Rindes. *Dtsch Tierärztl Wschr* 87:333-335, 1984.
41. Tulleners E, Hamir A: Effects of teat cistern mural biopsy and teatoscopy stab versus longitudinal incision with or without tube implant on incisional healing in lactating cattle. *Am J Vet Res* 51:1257-1266, 1990.
42. Weigt U, Agthe O, Bleckmann E, et al: Anwendung eines penicillinasefesten Langzeitpenicillins (Bayer 9035 NS) bei Zitzenverletzungen der Rinder. *Prakt Tierarzt* 52:559-563, 1971.
43. Weichselbaum H, Baumgartner W, Schoder G: Einfluß der Dauer des temporären Trockenstellens eines Euterviertels bei Kühen auf Milchmenge und Milchqualität. *Dtsch Tierärztl Wschr* 102:353-358, 1995.
44. Wilhelm U, Schebitz J: Diagnose und Therapie proliferativer Wucherungen in der Zitzenzisterne unter Sichtkontrolle mit einem Miniaturrektoskop. *Tierärztl Prax* 7:305-309, 1979.
45. Will S, Würgau T, Fraunholz J, et al: Sonographische Befunde an der Papilla mammae des Rindes. *Dtsch Tierärztl Wschr* 97:403-406, 1990.
46. Witzig P, Hugelsdorfer J: Abklärung von Zitzenstenosen beim Rind mit Hilfe des Doppelkontraststrahlungs. *Schweiz Arch Tierheilk* 126:155-163, 1984.
47. Witzig P, Rüschi P, Berchtold M: Diagnose und Therapie von Zitzenstenosen beim Rind unter besonderer Berücksichtigung des Röntgens und der Thelotomie. *Vet Med Nachr (Bayer)* 2:122-132, 1984.
48. Wollrab J: Über milchabflussbehindernde Veränderungen im Bereich der Euterzisterne und ihre röntgenologische Darstellung. *Mh Vet Med* 18:28-32, 1963.



“Milk Them For All Their Worth

is a one-of-a-kind book that will be extremely valuable to dairy farmers and related personnel in their efforts to produce one of our most nutritious foods and it deserves a prominent spot in their libraries...a valuable resource.”

*Harold Amstutz, D.V.M.
Professor Emeritus, Purdue University*

© Copyright American Association of Bovine Practitioners; open access distribution.

Cows are our passion!

**Vaca Resources
Donald E. Sanders, DVM
Diplomate American College of Theriogenology**

985 Norwood Avenue
Urbana, Ohio 43078 U.S.A.
Phone 937-484-6814
Fax 937-652-2060
dsanders@vacaresources.com
www.vacaresources.com

Place your order for *Milk Them For All Their Worth!* - Dr. Sanders' Guide to Milk and Money. Orders may be placed on-line through our secure server, phone, fax or mail.