

Calcium Chloride, Practical Necrotising Agent

L.M. Koger, D.V.M.,
Department of Veterinary Clinical Medicine & Surgery
College of Veterinary Medicine
Washington State University,
Pullman, Washington 99164

Calcium chloride (CaCl_2) is included in many electrolyte solutions used in medicine. Specific indications for the calcium ion are cardiac arrest and hypocalcemia. A commercial product containing 12% CaCl_2^* was formerly widely used in the treatment of hypocalcemic syndromes including so-called "milk fever." The label carried warning to "avoid perivascular delivery" and it was common knowledge that perivascular injection caused discrete local dry gangrene (1). The following report is part of an effort to make serendipitous use of an adverse hazard and utilize it to accomplish chemosurgical benefits in dehorning, castration, and destruction of unwanted tissue.

Histopathological examination of experimental lesions caused by injections of CaCl_2 suggested that the pathogenesis was ischemic necrosis produced by osmotic injury from the hypertonic solution causing thrombosis and occlusion (2). Gross and microscopic examination of tissue sections from biopsies of injected tissue revealed areas of coagulation necrosis surrounded by inflammatory reaction. The nuclei of cells were remarkably well preserved for several days after the injection, but both nuclei and cells were shrunken.

Following intradermal injection of small amounts, e.g., 0.1 ml., almost instantaneously, an edematous erythematous zone developed circumferentially, delineating the area of dry gangrene that became apparent after a period of 3-10 days.

Practical applications were the destruction of superficial hyperplasia and neoplasia (warts, sarcoids, and tumors, particularly if encapsulated and/or pedunculated). Failures occurred when the target tissues were too fragile to retain the injected bleb or the needle puncture wound admitted leakage.

Various solutions of CaCl_2 were tested. A 50% aqueous solution was effective and convenient to prepare, and was used exclusively in the early trials. The heat of hydration produced temperatures of approximately 80°C , and multiple dose vials remained stable after months of repeated withdrawals. Such solutions were relatively non-irritating to the operator's skin, even when splashed in the eyes. In a few cases (2) blistering and loss of hair occurred adja-

cent to the site of injection presumably from leakage or spillage.

Calcium Chloride Dehorning

Young calves were dehorned by injection into the horn bud (3). Restraint was either manual or preferably by drug sedation (xylazine).** The advantages were those of a simple, easy procedure without the hazards of hemorrhage, stress, sinusitis and infection. In order to visualize the horn bud, often irregular in shape, it was necessary to clip the hair away from the bud and scrub the debris off the keratinized skin. Care was necessary to insure that the point of injection and the amount of injection insured a peripheral swelling completely around the horn bud (4). The point of the needle was placed in the center of the area to be destroyed, and slow deliberate injection was necessary to produce a uniform ring of swelling around the germinal epithelium, sometimes requiring repositioning the needle point but minimizing the number of puncture wounds. Dose was dependent on development of the horn bud and ranged from 0.75-2.0 ml. After using many syringe and needle combinations, a glass and metal tuberculin syringe, screw adapter with 22 gauge $\frac{1}{4}$ needle was the preferred combination. Although dehorning has been successful in calves up to 51 days of age, recommendations have been limited to the first week of age because some calves with precocious horn development are difficult to inject by the 8th day. As the periosteum of the cornual process became firmly attached to the keratinized horn bud, it became increasingly difficult to deposit the solution for uniform necrosis of all of the germinal epithelium. If any viable horn bud was left, a scur developed.

Experimentation revealed advantages for alcoholic solutions of CaCl_2 in ruminants, and tinctures of CaCl_2 have been used since June 1976. Of the first 100 calves injected† with alcohol solutions, at the end of the observation period (approximately age two months), 96 appeared to have been completely dehorned, and only four exhibited any horn development. Saturated solutions of CaCl_2 in both ethanol and isopropyl alcohol were comparably effective.

CaCl_2 Castration

This report of the intratesticular injection of alcohol solutions of CaCl_2 for castration was limited to calves, with only incidental mention of promising preliminary results in pigs, dogs, cats, kid goats, and lambs. Small gauge needles (20-27 ga) were used to

*Chlorodex, Haver Lockhart Labs, Shawnee, Kansas 66201.

**Rompum: Haver Lockhart Labs, Shawnee, Kan. 66201.

†Holstein calves, 30 to 10 days of age, at the WSU Knott Dairy Center.

minimize leakage and of sufficient length to place approximately 25-30% of the dose near the head of the epididymis with remainder distributed throughout the testicle.

After antiseptic preparation of the skin, the testicle was secured firmly against the skin of the scrotum. The site of injection was near the tail of the epididymis. With adequate restraint there was little evidence of pain other than the skin prick. On withdrawal, care was taken to complete the injection before the tip of the needle approached the tunic to prevent the escape of solution and consequent necrosis of the scrotum. The dose depended on the size and development of the testicle and ranged from 1.0 to 1.5 ml per 45 kg of body weight.

Some calves showed only a few signs of discomfort, others laid down after release and were reluctant to move for a few hours, but in any case exhibited less stress than following surgical castration. The resulting orchitis subsided in 3-6 days; induration was followed by atrophy that after 1-3 months left an empty scrotum containing only a cord-like remnant.

In animals old enough to exhibit secondary sex characteristics, changes in behavioral patterns were noticed within two weeks post injection, and they became typical steers.

In earlier trials when excess amounts were injected with resulting leakage, hypostatic dry gangrene of the scrotum occurred. It was followed by uneventful

sloughing and rapid healing without complications or myiasis. No skin necrosis was observed in the above trial involving 45 young Holstein bull calves.

The saturated alcoholic solutions were less concentrated than possible aqueous solutions of CaCl_2 , but the above results indicated advantages of less pain, less peripheral inflammatory reaction and more consistent end results.

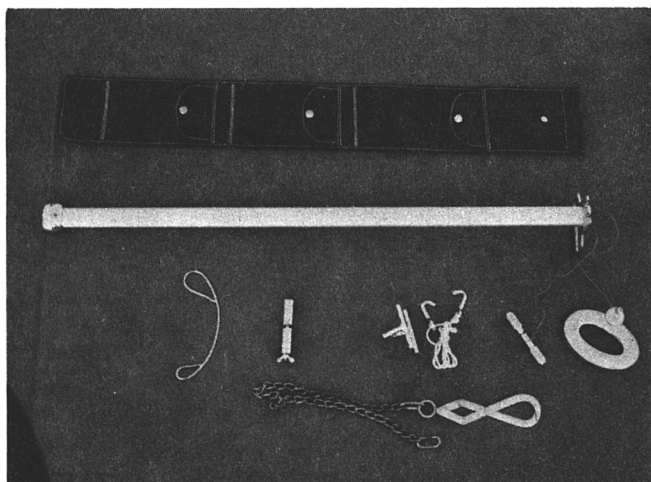
Discrete destruction of specific target tissues by minute amounts of local injections of CaCl_2 , a common, non-toxic, inexpensive reagent, and without open surgical wounds with their consequent complications appeared to have many possibilities as chemosurgical alternatives. With cooperation of the WSU Animal Science Dept., several projects are underway to explore, test, and evaluate possible techniques.

References

1. Jenkins, W.L., and Clark, D.R.: A Review of Drugs Affecting the Heart. *JAVMA*, 171 (July 1, 1977) No. 1:88. — 2. Personal communication. G.R. Spencer, Dept. of Vet. Path., Washington State University, Pullman, WA. Aug. 15, 1975. — 3. Koger, L.M.: Calcium Chloride for Prevention of Horn Bud Growth in Calves. *JAVMA*, 169, No. 2 (July 15, 1976): 219-221. — 4. Koger, L.M.: Dehorning by Injection of Calcium Chloride, VM/SAC 71, No. 6, June 1976: 824.

This paper was presented as item #451 of the Annual Meeting of the American Society of Animal Science, University of Wisconsin, July 24-27, 1977.

New Imported Obstetrical Instruments from Jorgensen Laboratories Inc.



New, lightweight Utrecht model fetatome with hardened metal head. Includes modified grip with knotted plate for obstetric chains.

Curved wire guide

Obstetrical wire grips

Combination obstetrical wire container and grip

Double action Krey hook. Available with stainless steel chain.

Ostertag's eye hooks

Fetatome case

Available from Distributors. Please visit our convention booth.

**Dr. Jorgensen Laboratories
P. O. Box 872
Loveland, Colorado 80537**