

Clinical Assessment and Surgical Management of Umbilical Masses in Calves

Donald F. Smith, D.V.M.
Department of Surgical Sciences
University of Wisconsin-Madison
2015 Linden Drive West
Madison, Wisconsin 53706

Most swellings or masses of the umbilical area of calves can be classified as simple umbilical hernias. However, a significant percentage of hernias are complicated by another pathologic process. Some masses are not hernias at all even though they appear to be on casual examination. The purpose of this presentation is to:

1. Describe the differential diagnosis of umbilical masses in calves;
2. Describe the most reliable diagnostic parameters;
3. Describe the medical and surgical management with special reference to etiology and prognosis.

History:

The age of the calf and the rapidity of onset of clinical signs is important. Was the umbilicus normal at birth or was omphalophlebitis present? Was umbilical swelling noticed early in life or not until the calf was several weeks or months of age? Is the mass enlarging; if so, how rapidly? Has purulent material drained from the umbilicus? Is the calf of normal size and condition for its age? Are dysuria, stranguria or pollakiuria present?

Physical Examination:

A general physical examination, noting the vital signs and condition of the calf, is important.

With respect to the umbilical mass, 4 criteria should be carefully evaluated:

1. Visual Appearance— size, shape, degree of hyperemia
 - positional relationship to umbilicus
 - presence of drainage from umbilicus
 2. Palpation - Consistency:
 - doughy - abomasum mem-
 - branous - omentum firm -
 - umbilical stalk or
 - abscess
 - Fluctuant - thin-walled
 - abscess
- Temperature: increased heat - inflammation (abscess)
- Sensitivity: pain - inflammation (abscess)

3. Hernial Ring—Is a hernial ring present? If so, is it a complete ring (circumferential) or is there an area at either the cranial or caudal pole where the ring is indistinct (incomplete)?
4. Reducibility—This describes the ability to massage or “milk” the contents of the mass through the abdominal wall defect into the normal contour of the abdomen. The amount of the mass which is reducible indicates the portion of the mass which is a hernia (provided adhesions are not present).

Differential Diagnosis:

1. *Umbilical Hernia (uncomplicated):*

An umbilical swelling is usually seen during the first few days or weeks of life. The mass usually enlarges at a uniform rate as the calf grows. Typically, the lesion is hemispherical or cylindrical and is centered dorsal to the umbilicus. Palpation reveals either membranous (omentum) or firm and doughy (abomasum) contents, or both. The mass is completely reducible through a distinct and uniformly smooth ring. On occasion, a firm, tubular cord can be palpated extending dorsocranial or dorsocaudal from the umbilicus through the hernial ring into the abdomen. This is the remnant of the umbilical vein (cranial) or the urachus or umbilical artery (caudal).

These calves are in good physical condition and rarely show signs of gastrointestinal dysfunction. Occasionally, the contents of the hernia become incarcerated, in which case the calf may become anorectic or show signs of colic.

2. *Umbilical Hernia with Localized Fibrotic Core or Abscess:*

The history of these calves often indicates that a prominent umbilical cord has been present since birth. An enlarging umbilical mass (the hernial component) is often not present until the calf is several weeks of age.

The calves are in good condition. The visual appearance of the mass is similar to that of a simple umbilical hernia. On palpation, however, 2 components are detected: a membranous or doughy reducible portion situated dorsally, adjacent to the body wall, and a firm nonreducible portion located ventrally adjacent to the umbilicus. Skin overlying the nonreducible portion is firmly attached to the mass. A

distinct and uniformly smooth hernial ring is present.

The localized swelling at the umbilicus is usually chronic inflammatory tissue, or a localized abscess, caused by omphalophlebitis. It is possible that the infection predisposes to a weakness of the body wall, thus initiating the hernia.

3. Umbilical Hernia with Infected Vestige of Urachus:

The typical history indicates intermittent purulent drainage from the umbilicus starting at 1 to 2 weeks of age, followed several weeks later by the appearance of a rapidly enlarging mass. The calves are thin and in poor body condition. Concurrent diseases, such as pneumonia or ringworm, may be present. Dysuria and stranguria, and occasionally pollakiuria, are sometimes observed.

The mass is large and has a broad base. The dorsal aspect is easily reducible. At the ventral aspect, a firm, cylindrical, 3-5 cm diameter stalk courses dorsocaudally from the umbilicus into the abdominal cavity. The stalk is painful to palpation and pus can be expressed from this opening at the umbilicus.

The hernial ring is described as incomplete because it cannot be distinctly palpated in the area where the stalk enters the abdomen.

4. Umbilical Hernia with Infected Vestige of Umbilical Artery:

These calves appear similar to those described above (infected urachus) except that abnormal urination is less likely to be present. The infected stalk also courses dorsocaudad from the umbilicus, although it is actually going to one side of the bladder. The differentiation is usually not made until surgical exploration is performed.

5. Umbilical Hernia with Infected Vestige of Umbilical Vein:

These calves also appear similar to those described above. However, because the liver is often involved by extension of the umbilical vein, other septic foci, in particular septic arthritis, is sometimes present. As would be expected, urination is not affected.

The umbilical stalk can be palpated as coursing dorsocranial towards the liver.

6. Umbilical Abscess:

In calves with umbilical abscesses, the swelling is often present from birth. In older calves, however, a rapidly enlarging mass may be evident at any time up to 1 to 2 years of age. Drainage from the umbilicus may be intermittent, although sometimes it is never observed.

The calves are in poor physical condition. The umbilical mass has a broad base and the overlying skin is hyperemic and warm. The contents are either fluctuant or firm, depending on the thickness of the abscess capsule. The mass is not reducible and there is no palpable hernial ring.

Peripheral leukocytosis with neutrophilia is a prominent hematologic finding. Large bore needle aspiration (14 or 16 gauge) reveals foul-smelling purulent material. The bacteria commonly isolated include *Corynebacterium pyogenes* or *E. coli*.

7. Enlarged Umbilical Stalk:

An umbilical swelling is usually observed at a young age and the size of the mass changes minimally as the calf grows. A transient purulent discharge is reported in some cases.

The calves are in good general condition. The mass is usually cylindrical with a narrow base. The contents are firm and not painful to palpation. There is no hernial ring and the mass is not reducible.

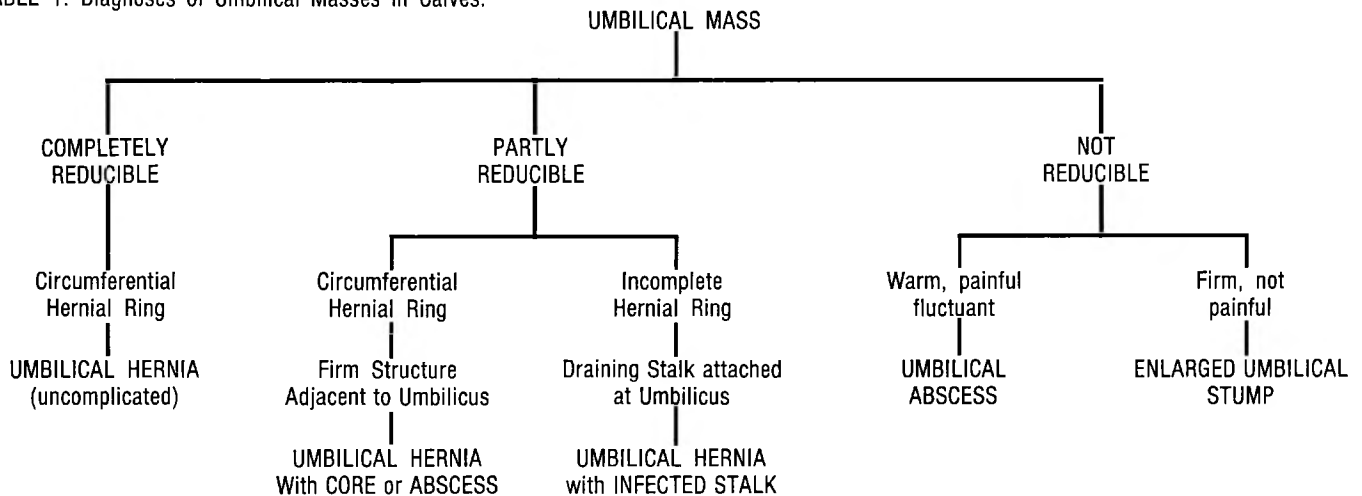
Examination of the mass following surgical removal typically reveals chronic active omphalophlebitis.

Surgical Repair:

Preoperatively, calves should be kept off feed for 12 to 24 hours, depending on age, size of abdominal wall defect and diagnosis. Anesthesia is achieved by tranquilization and local infiltration of lidocaine. In some cases, general anesthesia may be indicated. The calf is restrained in dorsal recumbency and the ventral part of the abdomen is prepared for aseptic surgery.

In calves with simple umbilical hernias, surgical repair is straight-forward. An open herniorrhaphy is advocated in

TABLE 1. Diagnoses of Umbilical Masses in Calves.



most cases as it allows identification of intra-abdominal structures associated with the hernia, and facilitates closure of the abdomen. In some cases, remnants of an umbilical vessel or the urachus may be identified as thin tubular stalks coursing dorsocaudad or dorsocranial from the umbilicus. These should be ligated and transected.

Abdominal closure is achieved by one of two methods. The simple apposing pattern involves the direct apposition of fascial edges in a side-to-side manner using simple interrupted sutures or near-far-far-near sutures. The overlapping mattress suture pattern is advocated by some surgeons; however care must be taken to prevent tissue ischemia due to excessive tension on the suture line. Either absorbable or non-absorbable suture material may be used. In the repair of large abdominal defects, the use of surgical mesh may be indicated.

In calves with an umbilical hernia plus a circumscribed fibrotic mass, the mass should be excised with the hernial sac. Adhesions involving the greater omentum or abomasum may be evident and may necessitate resection.

Calves with a draining umbilical tract accompanying an umbilical hernia present a special problem. Before surgery, the tract should be flushed to reduce the risk of contamination at the time of surgery. Then the tract should be packed with an antiseptic-soaked gauze and the external fistula oversewn. This prevents the inadvertent discharge of purulent material from the sinus during surgery. The abdomen is then opened as in a normal herniorrhaphy. The umbilical stalk is traced to its origin either at the bladder or at the liver. If the stalk attaches to the bladder, the apex of the bladder should be resected so that no residual stalk remains within the abdomen. If the stalk is a remnant of the umbilical

artery, the stalk is resected as far proximally as possible. If the stalk is a remnant of the umbilical vein and courses to the liver, complete resection is seldom possible. However, it is important to resect the stalk at the most proximal part which is accessible. If the umbilical vein infection leads to a liver abscess, marsupialization of the umbilical vein provides the only realistic method for safely dealing with the infection. Omental adhesions are often present adjacent to these stalks. These are usually hemorrhagic and should be resected with care. Following removal of the stalk, routine herniorrhaphy is performed.

In calves with umbilical abscesses, the abscess should be drained and treated conservatively for several days to 2 weeks before surgical intervention is attempted. This allows for contraction of the abscess cavity as well as reducing the risk for contamination at surgery. Surgical resection may not always be indicated; however, the presence of an intra-abdominal focus of infection makes it wise to consider surgery. In addition, removal of the abscess core provides a cosmetic advantage.

Surgical repair of masses consisting of umbilical stalks involves complete resection of the stalk. An intra-abdominal approach is again recommended as it might reveal abdominal extension of the mass.

Summary:

With accurate preoperative clinical diagnosis, prognosis for the surgical repair of umbilical masses in calves is very good. Table 1 outlines the physical criteria of abdominal masses so as to arrive at a diagnosis in a step-wise manner.